

Doctoral School in Medical Sciences

The manuscript title

U.D.C: 616.311-07:616.36 002.2(043.2)

IVASIUC Irina

**ASSESSMENT OF ORAL MUCOSAL LESIONS IN PATIENTS
WITH CHRONIC VIRAL HEPATITIS B AND C**

323.01 – Dentistry

Summary of the Ph.D. thesis in Medical Sciences

Chişinău, 2024

The Ph.D. thesis was developed at the Department of Dental Propaedeutics "Pavel Godoroja" of the Faculty of Dentistry at "Nicolae Testemițanu", State University of Medicine and Pharmacy, within the University Dental Clinic and the "Dia Dents" Dental Clinic.

Scientific advisor:

UNCUȚA Diana

Dr. habil., sci., associate professor

Co-tutor scientific advisor:

COSTEA Daniela-Elena

PhD med. sci., university professor

Members of the guidance committee:

SPÎNU Constantin

Dr. habil., sci., university professor

PÂNTEA Victor

Dr. habil., sci., universitar professor

BAJUREA Nicolae

PhD med. sci., associate professor

The Ph.D. defense will take place at 30 October 2024 at 14:00 o'clock at the "Nicolae Testemițanu" SUMPh, 165 Ștefan cel Mare și Sfânt bd., office 205 at the public defense meeting of the Ph.D. thesis, approved by the decision of the Scientific Council of the Consortium on 26.06.2024 (*minutes no. 44*).

The public Ph.D. thesis defense committee:

President:

Fala Valeriu

Dr. habil., sci., university professor, c. m. of AȘM

Secretary:

Spinei Aurelia

Dr. habil., sci., associate professor

Members:

Uncuța Diana

Dr. habil., sci., associate professor

Costea Daniela-Elena

PhD med. sci., university professor

Zănoagă Oleg

dr. șt. med, conf. univ.

Official reviewers:

Bajurea Nicolae

PhD med. sci., associate professor

Tatarciuc Monica-Silvia

PhD med. sci., university professor

Popa Cristina

PhD med. sci., associate professor

Author

IVASIUC Irina

© IVASIUC Irina, 2024

CONTENTS

INTRODUCTION	4
1. ORAL MUCOSAL CONDITIONS IN PATIENTS WITH CHRONIC VIRAL HEPATITIS	5
2. MATERIALS AND METHODS	6
2.1. General characteristics of the research methodology	6
2.2. Investigation and treatment methods and diagnostic criteria	8
2.3. Statistical data processing methods	10
3. CLINICAL AND EPIDEMIOLOGICAL ANALYSIS OF ORAL MUCOSAL CONDITIONS IN PATIENTS WITH CHRONIC VIRAL HEPATITIS B AND C	10
3.1. Clinical characteristics of oral mucosal conditions	10
3.2. Clinical characteristics of oral mucosal conditions in patients without chronic viral hepatitis B and C	11
3.3. Clinical characteristics of oral mucosal conditions in patients with chronic viral hepatitis B and C	12
3.4. Comparative analysis of treatment outcomes in patients with oral mucosal conditions associated or not with chronic viral hepatitis B and C	12
3.5. Clinical characteristics of oral lichen planus	14
SYNTHESIS OF RESULTS OBTAINED	16
GENERAL CONCLUSIONS AND PRACTICAL RECOMMENDATIONS	19
REFERENCES	20
LIST OF PH.D. THESIS-RELATED PUBLICATIONS	21
ANNOTATION	25

INTRODUCTION

Relevance and importance of the research. Oral mucosal lesions (OML) are defined as any abnormality or change in the surface or color of the oral mucosa, inflammation, or loss of surface integrity, which can result from local pathology or secondary lesions of systemic diseases [3, 9, 13]. The prevalence of oral mucosal conditions (OMC) varies significantly worldwide, depending on the region, country, and data source, ranging from 4.9% to 84.0% [3, 4]. Despite estimates that around 90% of the global population experiences some type of oral disease at some point in their lives, these lesions often receive inadequate attention in public health policies [8].

Extrahepatic manifestations (EHMs) associated with hepatitis C virus (HCV) and hepatitis B virus (HBV) infections can affect various organ systems, resulting in significant morbidity and mortality. EHMs are common and polymorphic, with up to 74-75% of patients with chronic HCV infection displaying at least one EHM, most frequently involving the oral cavity. Approximately 68.0% of HCV-infected patients are diagnosed with lichen planus (LP), and up to 87.5% of those with chronic viral hepatitis exhibit other autoimmune-mediated conditions (AIMCs). Given the often asymptomatic or mild nature of chronic hepatitis B and C, EHMs may serve as the first or only clinical sign or symptom of infection in approximately 70% of patients [1, 7, 11].

Chronic viral hepatitis is a significant public health concern in the Republic of Moldova. Although the incidence of acute viral hepatitis has declined, the prevalence of chronic viral hepatitis remains high and continues to rise. The prevalence of chronic hepatitis B (HBV) increased from 206.4 cases per 100,000 population in 2000 to 820.0 cases per 100,000 in 2020, and chronic hepatitis C (HCV) cases rose from 43.4 to 421.1 cases per 100,000 population over the same period [12].

Furthermore, despite earlier epidemiological studies indicating a high prevalence of OMLs in certain countries, especially among the elderly and geriatric populations (40.0-84.0%), there is currently a limited amount of global research on the prevalence and distribution of OMLs. Additionally, there is a lack of data on the association of these conditions with HCV and HBV infections in European countries [9].

Thus, awareness and recognition of EHMs, including OMLs, are significantly important not only for facilitating the early diagnosis and management of these lesions but also for identifying HCV or HBV infections and implementing appropriate measures to prevent their transmission.

The purpose of the study is to conduct a comprehensive analysis of oral mucosal disorders associated with chronic viral hepatitis B and C and to develop an optimal plan for the prophylactic therapy and dynamic monitoring of these patients.

Research objectives:

1. To investigate the implications of oral mucosal conditions in individuals with chronic viral hepatitis B and C.
2. To develop a diagnostic protocol suitable for detecting oral mucosal conditions in patients at various stages of clinical observation, both with and without chronic viral hepatitis B and C.
3. To compare diagnostic outcomes of oral mucosal conditions between patients with chronic viral hepatitis B and C and those without hepatitis.
4. To develop therapeutic guidelines for managing oral mucosal conditions in patients with chronic viral hepatitis B and C.
5. To design a monitoring and prevention program for oral mucosal conditions in patients with chronic viral hepatitis B and C.

Scientific novelty and originality. The study highlighted the diagnostic, clinical, and histopathological peculiarities in patients with OMLs associated with HBV and HCV infections. Specific markers of chronic viral hepatitis B and C were identified in patients with OMCs.

Theoretical significance of the study. This research outcomes are aimed to deepen the understanding and confirm the unique clinical manifestations in patients suffering from OMCs associated with HBV and HCV infections. Therapeutic management was determined and the implications of OMCs were explained at various stages of clinical monitoring in patients with HBV and HCV infections.

The practical significance of this study lies in the development and implementation of a diagnostic protocol for OMC in patients with chronic hepatitis B and C. By integrating this protocol into clinical practice, it will enable faster diagnosis of patients, reduce the progression rate of OMCs in chronic viral hepatitis patients, and improve treatment outcomes economically by reducing disease recurrence and temporary disability duration.

Approval of Ph.D. thesis results: The study results were presented and discussed at the following national and international scientific forums: The 8th International Medical Congress for Students and Young Doctors. Chişinău, Republic of Moldova, September 24-26, 2020; Congress commemorating the 75th anniversary of Nicolae Testemiţanu State University of Medicine and Pharmacy in the Republic of Moldova. Chişinău, Republic of Moldova, October 21-23, 2020; XXIX International Online Symposium "Innovative Technologies in Dentistry". Omsk, Russia, March 3-4, 2021; National Scientific Conference with International Participation "Personalized Surgery in Adults and Children – Surgery of the Future". Chişinău, Republic of Moldova, March 24-25, 2022; The 37th Balkan Medical Week "Perspectives of Balkan Medicine in the Post-COVID-19 Era". Chişinău, Republic of Moldova, June 7-9, 2023; Scientific Conference "Digital Technologies in Multidisciplinary Dentistry". Chişinău, Republic of Moldova, September 9-10, 2023.

Keywords: oral mucosal conditions, lichen planus, oral lichen planus, chronic viral hepatitis B, chronic viral hepatitis C, hepatitis B virus, hepatitis C virus, extrahepatic manifestations.

1. ORAL MUCOSAL CONDITIONS IN PATIENTS WITH CHRONIC VIRAL HEPATITIS

Hepatitis C virus (HCV) is frequently associated with oral mucosal conditions (OMCs) that have potential for malignant transformation or are already malignant. HCV serves as a triggering factor for some of these lesions, or can at least influence their progression. The association is notably strong with oral lichen planus (OLP), and recent epidemiological data strongly suggest links with Sjögren's syndrome (SS) and oral squamous cell carcinoma (OSCC) [6].

OLP is a chronic inflammatory condition marked by alternating periods of remission and flare-ups, with a potential risk of malignancy. It represents a cell-mediated response to various external antigens, modified autoantigens, or superantigens. The etiology and pathogenesis of this disease are intricate and incompletely understood, requiring further research, especially given the risk of malignant transformation [4, 10]. OLPs exhibit distinctive clinical morphology and distribution patterns, yet they manifest in wide range of forms. Therefore, early diagnosis and treatment, coupled with regular patient monitoring, are imperative [5, 10].

There is strong evidence relating HCV to OLP and suggesting its probable involvement in its pathogenesis, although this association may vary in significance across different geographical regions [2, 6]. Conversely, HCV infection is often asymptomatic, largely underdiagnosed, and can

lead to serious consequences. Comprehensive prospective population-based studies using rigorous sampling methods are necessary to elucidate the relationship between HCV and OLPs and ensure the findings are representative [2].

These findings emphasize the need for regular oral examinations for patients with both HCV and HBV, as well as for a routine *screening* for HCV and HBV infections in individuals with OLP [2, 8, 10].

2. MATERIALS AND METHODS

2.1 General characteristics of the research methodology

This study is a prognostic cohort investigation designed to: 1) evaluation of oral manifestations in OMCs among patients with chronic viral hepatitis B and C; 2) highlight the impact of OMC in patients with chronic viral hepatitis B and C at various stages of clinical monitoring; 3) develop a comprehensive diagnostic and treatment protocol for OMC in patients with chronic viral hepatitis B and C.

The sample included 150 adult patients of both sexes, aged over 18 years, with OMC associated or not associated with both chronic viral hepatitis B (HVB) and C (HVC) at different stages of disease progression. Patients were randomly divided into two groups: 75 patients OMC-associated HVB or HVC (study group – SG) and 75 patients with OMC without chronic viral hepatitis (control group – CG) (Figure 1).

For better research accuracy, several inclusion and exclusion criteria were strictly followed, thereby delineating the study and focusing on a representative cohort. The inclusion criteria for the study were as following:

1. Patients with chronic viral hepatitis B or C in the phases of immunotolerance (minimal activity), immune clearance (immunoactivity), immune control (inactive carrier), and immune reactivation (immune escape).
2. Patients with OMLs: oral candidiasis, oral lichen planus, recurrent chronic aphthous stomatitis, herpetic stomatitis, erythema multiforme, oral lichenoid lesions (OLL), burning mouth syndrome, leukoplakia, benign and malignant tumors.
3. Adult patients (≥ 18 years).
4. Patients who have provided informed consent.

Exclusion criteria from the study comprised:

1. Age < 18 years.
2. Patients with acute viral hepatitis B or C.
3. Patients with advanced liver failure or hepatocellular carcinoma.
4. Patients with a history of surgery, administration of medications and dental restorative materials, or conditions that could affect the oral mucosa.
5. Patients with recent maxillofacial trauma.
6. Patients administering antiviral treatment for any other systemic conditions.
7. Patients undergoing radiotherapy or chemotherapy.
8. Patients who do not adhere to oral hygiene and prophylaxis conditions.
9. Pregnant or breastfeeding women.
10. Patients who did not consent to participate in the study.

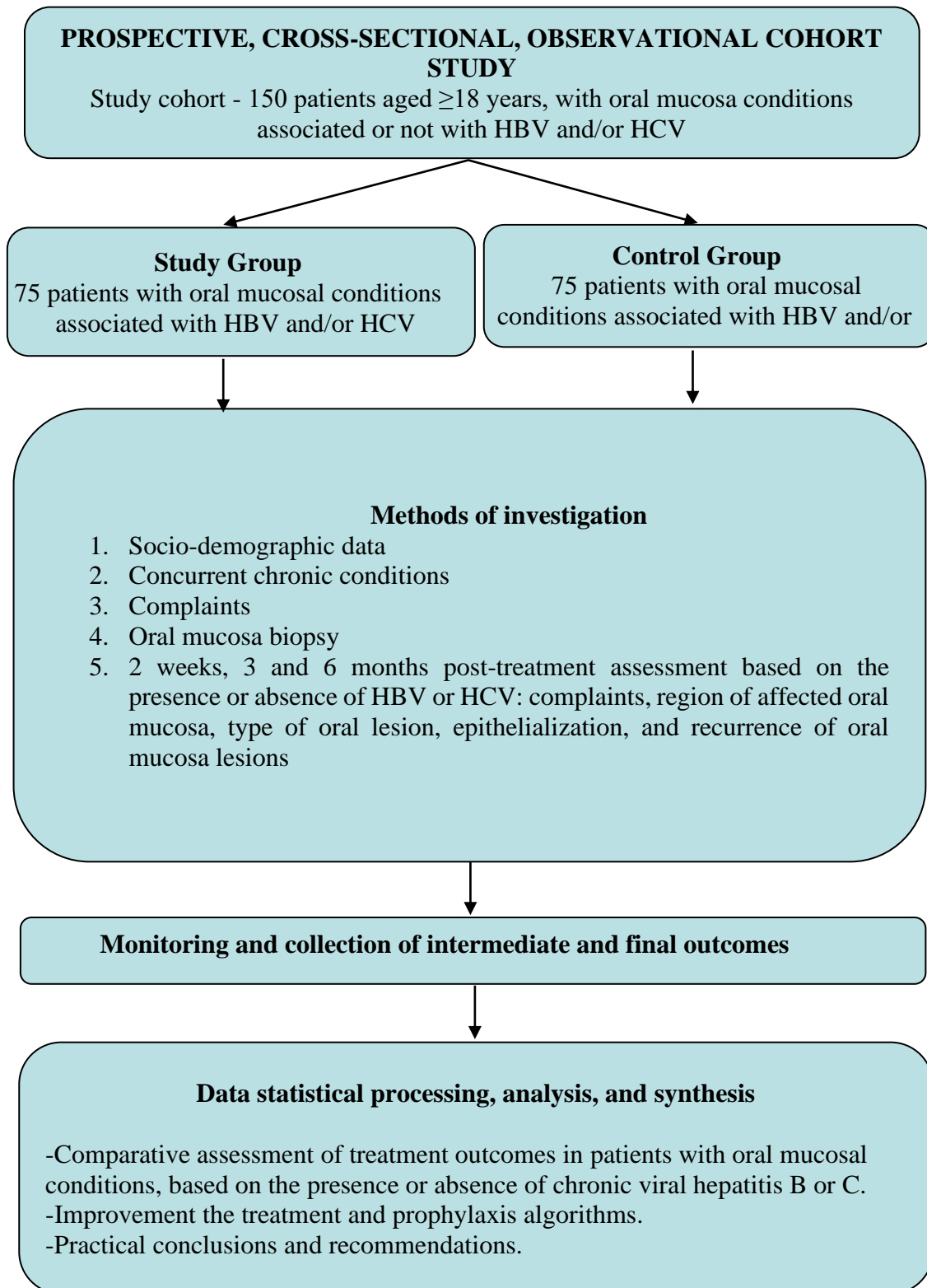


Figure 1. **Study design**

For all patients included in the study, detailed medical history was taken, clinical examinations were conducted, and relevant investigations were performed as needed. The final diagnosis was confirmed based on clinical criteria, cytological analysis, and histopathological examination.

2.2. Investigation and treatment methods and diagnostic criteria

All patients underwent a thorough survey and oral examinations to detect OMCs. For some oral lesions, the clinical diagnosis was definitive, and biopsy was not necessary. When necessary (unclear diagnosis based on clinical criteria or suspicion of malignancy), the biopsy of the oral mucosa with histopathological analysis was performed to confirm the clinical findings. Furthermore, the clinical presentations of certain oral lesions, including OLP and OLL, were found to be indistinct. The definitive diagnosis of these lesions was established based on biopsy results, allergy tests (patch tests), and consideration of medication histories that may induce OLL.

The patient's age, sex, medical history (including comorbidities), allergies, smoking, alcohol use, lesion locations, associated symptoms, prescribed treatments, and diagnostic investigations were recorded. Response to treatment was also recorded when follow-up was available.

Recurrent aphthous stomatitis, acute or chronic herpetic stomatitis, oral candidiasis, exudative polymorphous erythema, oral lichen planus, oral lichenoid lesions, burning mouth syndrome, leukoplakia, benign and neoplastic oral tumors were clinically (in typical forms) and histologically (in atypical forms) diagnosed.

The diagnosis of OMCs in patients with HBV or HCV involves five consecutive stages: 1) assessing the patient's local and overall health status; 2) correlating primary signs and symptoms with their current medical history; 3) establishing clinico-pathological correlations; 4) conducting a physical examination and reviewing medical records; 5) establishing a differential diagnosis.

The positive diagnosis of oral lichen planus (OLP) was made using criteria proposed by van der Meij and van der Waal, as well as the guidelines from the American Academy of Oral and Maxillofacial Pathology, based on:

1. Minimum clinical criteria including at least these criteria: symmetrical reticular keratosis, found bilaterally on the buccal mucosa in posterior regions, either alone or associated with other types of lesions.
2. The most widely accepted histopathological criteria concurrently present: a) chronic inflammatory cell infiltration, limited to the surface of the connective tissue, appearing as a dense and distinct "band," primarily composed of lymphocytes; b) hydropic (vacuolar) degeneration of the basal layer of keratinocytes; c) absence of epithelial dysplasia. [4, 5]

Clinically, six classic types of oral lichen planus (OLP) have been identified (Andreasen J, 1968):

1. Reticular or typical keratotic form.
2. Plaque-like form.
3. Atrophic, erythematous, or exudative-hyperemic form.
4. Erosive (ulcerative) form.
5. Papular form.
6. Bullous form [10].

Patients with multiple concurrent lesion types were classified by clinical severity, with the erosive form considered the most severe.

To accommodate larger patient cohorts, two additional classifications of OLP have been used. Silverman S (1985) categorized OLP into three types:

1. Reticular form – encompassing reticular, papular, and plaque-like forms.
2. Atrophic, erythematous form.
3. Erosive form – including erosive, ulcerative, and bullous forms [5].

Pindborg J (1997) proposed a two-type classification of OLP:

1. "Non-erosive" or "predominantly white" lesions – including reticular, papular, and plaque-like forms.
2. "Erosive" or "predominantly red" lesions – comprising atrophic, erosive, ulcerative, and bullous forms.

Chronic viral hepatitis B is characterized by the presence of hepatitis B surface antigen (HBsAg) for a duration of six months or longer. Diagnosis of HBV infection is confirmed based on established clinical, biochemical, and serological criteria (detectable HBsAg in serum via ELISA and HBV DNA through reverse transcription polymerase chain reaction) [11].

Chronic viral hepatitis C is defined as the persistence of HCV for 6 months or longer, accompanied by biochemical and histological changes, which can lead to severe complications such as liver cirrhosis and hepatocellular carcinoma. Diagnosis of HCV infection is based on accepted clinical presentation, biochemical criteria (e.g., Aspartate Aminotransferase, Alanine Aminotransferase), and serological criteria (presence of anti-HCV antibodies in serum and HCV RNA in serum, detected by reverse transcription polymerase chain reaction) [7, 11].

Clinical methods. All study participants underwent assessment using the survey methodology.

Primary data collection involved completing a specially designed structured clinical questionnaire for the present Ph.D. thesis, extracting data from medical records, documenting results from both initial and follow-up visits, clinical investigations, instrumental and laboratory findings before and after treatment.

The structured clinical questionnaire, specifically developed, comprised 48 questions covering socio-demographic details, concurrent chronic conditions, initial assessments, and subsequent ones at intervals of over 2 weeks, 3 and 6 months post-treatment, depending on the presence or absence of HBV and/or HCV: symptoms, affected OM region, and type of oral lesion, epithelialization, and recurrence of OMLs.

Histopathological examination of biopsy specimens taken from the oral mucosa was conducted at the Department of Pathology, Faculty of Medicine No. 2, Public Institution University of Medicine and Pharmacy "Nicolae Testemițanu".

The tissues were fixed in 10% neutral buffered formalin for 24-48 hours and subsequently embedded in paraffin wax. Histological sections were cut to a thickness of 3 μm. Standard staining techniques were applied, including Carazzi's hematoxylin and eosin, and van Gieson's picrofuchsin. The histopathological assessment was performed by anatomical pathologists.

Treatment methods. The treatment approach included the following methods:

1. Symptomatic Treatment:
 - Oral cavity debridement (removal of hard and soft deposits from dental surfaces using ultrasonic scaling and brushing).
 - Oral mucosa cleansing with antiseptic solutions (3% hydrogen peroxide, 0.06-0.12% chlorhexidine).
 - Topical gels and sprays containing local anesthetics such as Lidocaine or Benzocaine for pain relief and discomfort.
 - Anti-inflammatory ointments with corticosteroids to reduce inflammation.
 - Analgesic medications to alleviate pain and inflammatory symptoms.
2. Recommendations:
 - Avoidance of irritant foods: Patients are advised to avoid foods and beverages that may worsen symptoms, such as spicy, acidic, or hot foods.

- Hydration: Maintaining adequate hydration helps prevent oral mucosa dryness and worsening symptoms.
- Proper oral hygiene: Good oral hygiene practices, including brushing and flossing, can help prevent infections and maintain oral health.
- Consultation with specialized physicians as needed to monitor general conditions.
- Consulting an oncologic dentists in cases of suspected benign or malignant tumor conditions, including those at high risk of malignancy such as leukoplakia [10].

2.3. Statistical data processing methods

The initial study materials were inputted into an electronic database and processed using the functionalities and modules of SPSS version 16.0 for Windows (SPSS Inc., Belmont, CA, USA, 2008), alongside *Microsoft Office Excel 2019* on a personal computer via descriptive and inferential statistical procedures. Absolute and relative frequencies were calculated for nominal or categorical variables, while means, standard errors, and standard deviations of the mean were computed for quantitative or continuous variables (interval or ratio scale). The tests used included Pearson's χ^2 , χ^2 with Yates' correction, or Fisher's exact test for discrete variable comparisons. Normality of interval-scaled variables was assessed using the Kolmogorov-Smirnov test. Statistical differences in mean values between groups were determined using the "t" test or non-parametric tests. One-way analysis of variance with post-hoc tests and the non-parametric Kruskal-Wallis test were employed to assess multiple mean differences among study groups. Correlation analysis (Pearson's r , Spearman's ρ , Kendall's τ) evaluated the strength and direction of statistical relationships. Significance was attributed to differences with bilateral p-values <0.05.

3. CLINICAL AND EPIDEMIOLOGICAL ANALYSIS OF ORAL MUCOSAL CONDITIONS IN PATIENTS WITH CHRONIC VIRAL HEPATITIS B AND C

3.1. Clinical characteristics of oral mucosal conditions

The general study cohort included 150 patients aged 18 years or older (mean age 54.68 ± 12.8 ; Md – 56.0, IQR: 46.8-64.0 years), diagnosed with OMCs, comprising 27.3%; 95% CI: 20.7-34.8 of male patients and 72.7%; 95% CI: 65.2-79.3 of female patients.

Most commonly observed conditions among patients were OLP (38.0%; 95% CI: 35.0-45.9), burning mouth syndrome 21.3%; 95% CI: 15.4-28.4, recurrent chronic aphthous stomatitis 16.7%; 95% CI: 11.4-23.2, and oral candidiasis 11.3%; 95% CI: 7.0-17.1 (Figure 2). Overall, 88.7%; 95% CI: 82.9-93.0 of patients presented with a single condition, while 11.3%; 95% CI: 7.0-17.1 exhibited two concurrent diseases.

The most commonly affected sites of OM were the buccal mucosa in 76 patients (69.7%; 95% CI: 60.7-77.7), followed by the lips in 54 patients (49.5%; 95% CI: 40.3-58.8), the retromolar area in 53 patients (48.6%; 95% CI: 39.4-57.9), and the mucosa of the lateral tongue surfaces in 42 cases (38.5%; 95% CI: 29.8-47.9). Less frequently affected sites included the dorsal tongue surface in 20 patients (18.3%; 95% CI: 12.0-26.4), the gums in 18 patients (16.5%; 95% CI: 10.5-24.3), the hard palate in 9 patients (8.3%; 95% CI: 4.2-14.5), the buccal floor mucosa in 7 patients (6.4%; 95% CI: 2.9-12.2), the soft palate and uvula in 5 patients (4.6%; 95% CI: 1.8-9.8), and the pharyngeal mucosa in 2 participants (1.8%; 95% CI: 0.4-5.8) within the study cohort (Figure 3). Regarding the number of OMLs, 39.4% (95% CI: 30.6-48.8) of patients had 1 lesion, 37.6% (95% CI: 28.9-46.9) had 2 lesions, 18.4% (95% CI: 12.0-26.4) had 3 lesions, and 4.6% (95% CI: 1.8-9.8) had 4 lesions.

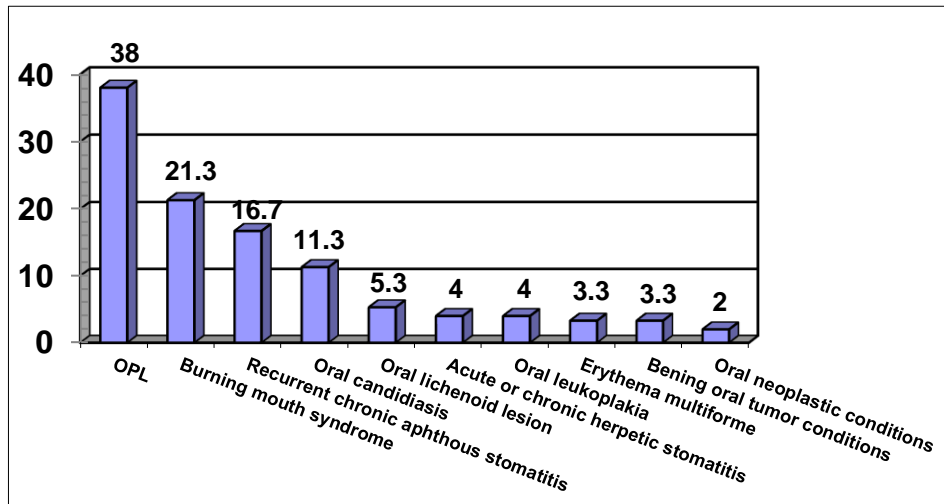


Figure 2. Distribution of patients with OMCs based on diagnosis (%).

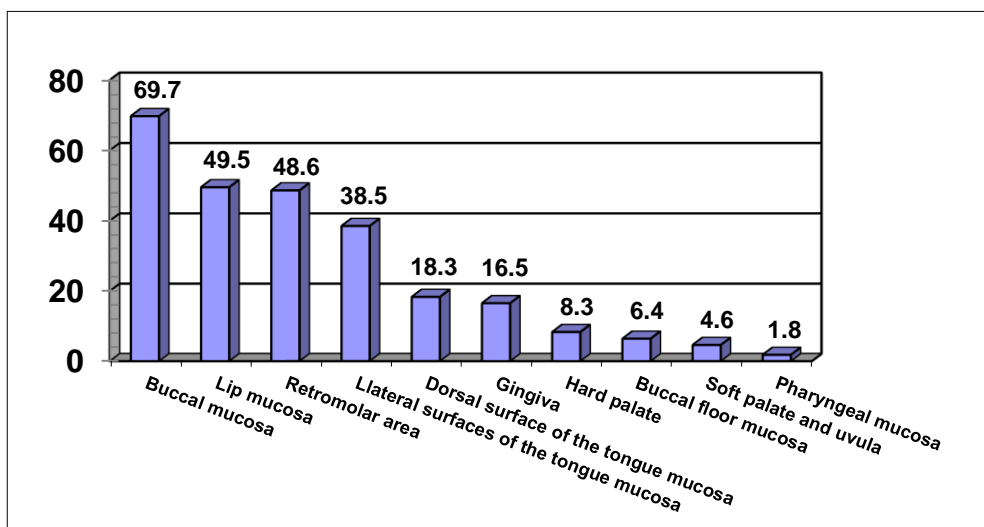


Figure 3. Distribution of patients with OMCs based on the affected area (%).

The dynamic assessment at 2 weeks and 3 months of follow-up treatment of patients diagnosed with OMCs showed notable findings, such as clinical improvement, reduced impaired regions of OMLs, epithelialization, and reduced OML number. However, an increased recurrence rate of OMCs (5.0%; 95% CI: 1.9-10.5 at 3 months post-treatment and 35.3%; 95% CI: 24.7-47.1 at 6 months post-treatment) contributed to a higher incidence of OMLs at 6 months post-treatment.

3.2. Clinical characteristics of oral mucosal conditions in patients without chronic viral hepatitis B and C

The study included 75 patients with OMCs, aged 18 years or older, who did not present chronic viral hepatitis B or C (mean age 52.76 ± 14.3 ; Md – 54.0, IQR: 44.0-65.0 years). Of these, 24.0%; 95% CI: 15.4-34.5 were males, and 76.0%; 95% CI: 65.5-84.6 were females.

The most frequently diagnosed conditions were OLP (38.7%; 95% CI: 23.2-56.2), followed by burning mouth syndrome (18.7%; 95% CI: 11.1-28.6), oral candidiasis (14.7%; 95% CI: 8.1-23.9), and recurrent aphthous stomatitis (13.3%; 95% CI: 7.1-22.4). Overall, 89.3%; 95% CI: 80.9-94.8 of patients had only 1 condition, while 10.7%; 95% CI: 5.2-19.1 had 2 concurrent conditions. Regarding the number of OMLs, 46.4%; 95% CI: 33.8-59.4 of patients had 1 lesion, 33.9%; 95%

CI: 22.6-46.9 had 2 lesions, 16.1%; 95% CI: 8.3-27.3 had 3 lesions, and 3.6%; 95% CI: 0.7-11.0 had 4 lesions.

Dynamic assessment at 2 weeks and 3 months post-treatment of patients with OMCs revealed significant outcomes: improvement in clinical presentation, reduction in affected OML areas, decreased rates of OMLs, and increased healthy OM areas.

However, the rise in OMCs recurrence rates (2.4%; 95% CI: 0.3-10.6 at 3 months post-treatment and 18.9%; 95% CI: 8.9-33.6 at 6 months) contributed to a statistically insignificant increase in the frequencies of affected OM regions (buccal mucosa and retromolar area), involving 3 OM areas, various types of OMLs (aphthae, ulcerations, plaques), 2 OML s, 3 OML lesions, and a statistically significant increase in erosion rates at 6 months post-treatment compared to those expected in subsequent periods.

3.3. Clinical characteristics of oral mucosal conditions in patients with chronic viral hepatitis B and C

The study included 75 patients aged 18 years and older (mean age years), with OMCs associated with chronic viral hepatitis B and C, including 30.7%; 95% CI: 21.1-41.7 males and 69.3%; 95% CI: 258.3-78.9 females.

The most commonly observed conditions were oral lichen planus (OLP) (37.3%; 95% CI: 27.0-48.6), burning mouth syndrome (24.0%; 95% CI: 15.4-34.5), and recurrent aphthous stomatitis (20.0%; 95% CI: 12.2-30.1). Overall, 88.0% (95% CI: 79.2-93.9) of patients presented with a single condition, while 12.0% (95% CI: 6.1-20.8) had two conditions concurrently. Concerning the number of OMC lesions, 32.1% (95% CI: 20.7-45.3) of patients had only 1 lesion, 41.5% (95% CI: 29.0-54.9) had 2 lesions, 20.8% (95% CI: 11.6-33.0) had 3 lesions, and 5.7% (95% CI: 1.6-14.3) had 4 lesions.

Dynamic assessment at 2 weeks and 3 months post-treatment of patients with OMCs revealed significant negative outcomes, viz. a statistically significant reduction in the OM pain relief improvement rate, a statistically significant increase in the frequency of OM pain and lacking dry sensation at 3 months post-treatment compared to 2 weeks, with a subsequent statistically significant decrease at 6 months compared to 3 months. Although the OML absence rate showed a consistent increasing trend, it did not reach statistical certainty, while the rate of non-significant epithelialization of OMLs decreased significantly at 3 months compared to 2 weeks post-treatment, followed by a subsequent genuine increase. The rate of epithelialization of OMLs increased significantly at 3 months compared to 2 weeks post-treatment, with a subsequent statistically significant decrease.

The increase in OMC recurrence rate (7.9%; 95% CI: 2.3-19.6 at 3 months post-treatment and 54.8%; 95% CI: 37.5-71.3 at 6 months) contributed to the rise in frequency of most affected OM regions (oral mucosa of lips, cheeks, retromolar area, dorsal and lateral surfaces of the tongue, gums, soft palate, and uvula) and the number of regions with 3 and 4 affected OM areas, as well as the number of OMLs (erosions, white striae, aphthae, ulceration, and plaques): with 2, 3, and 4 OMLs.

3.4 Comparative analysis of treatment outcomes in patients with oral mucosal conditions associated or not with chronic viral hepatitis B and C

The study groups included 75 patients per each, aged 18 years or older, with OMCs associated or not with chronic viral hepatitis B (HVB) and C (HVC). Patients in both study groups were similar in terms of mean age (56.60 ± 11.0 ; Md= 57.0, IQR: 50.0-64.0 years old in the study

group (SG) and 52.76 ± 14.3 ; Md – 54.0, IQR: 44.0-65.0 years old in the control group (CG), respectively), sex, living environment, frequency of complaints, concomitant chronic conditions, OMC diagnosis, type and number of OMLs, as well as in patient rates assessed dynamically at 2 weeks, 3 months, and 6 months of follow-up.

However, significantly fewer patients aged 18-39 years were included in the SG (5.3%; 95% confidence interval [CI]: 1.8-12.2) compared to the CG (17.3%; 95% CI: 10.1-27.1; $p < 0.05$). The rates of most complaints, concomitant chronic conditions, presence of OMLs, severe OML types (erosions, whitish striae, aphthae, ulcerations), and a higher number of concurrent OM signs (2, 3, and 4) were recorded in SG. The rates of other types of OMLs (plaques, growths), a lower number of concomitant OMLs (1), and the absence of lesions were found higher in the CG, although these differences did not reach a statistical significance.

The study of the affected regions in patients with OMCs revealed significant mucosal involvement of the lips (62.3%; 95% CI: 48.8-74.4 and 37.5%; 95% CI: 25.7-50.5, respectively; $p < 0.05$) and the retromolar area (60.4%; 95% CI: 46.9-72.7 and 37.5%; 95% CI: 25.7-50.5, respectively; $p < 0.05$) more frequently in SG. Although other affected regions were more common in SG cases, these differences did not reach statistical significance. SG patients exhibited a higher concurrent involvement of multiple regions: the incidence of lesions in 1 OM region (25.0%; 95% CI: 15.1-37.4 and 7.5%; 95% CI: 2.6-17.0, respectively; $p < 0.05$) and in 2 OM regions (42.9%; 95% CI: 30.5-55.9 and 20.8%; 95% CI: 11.6-33.0, respectively; $p < 0.05$) was significantly greater in CG. Similarly, involvement in 3 OM regions (47.2%; 95% CI: 34.2-60.5 and 23.2%; 95% CI: 13.7-35.4, respectively; $p < 0.01$) and in 4 to 6 regions (24.5%; 95% CI: 14.5-37.2 and 8.9%; 95% CI: 3.5-18.5, respectively; $p < 0.05$) was significantly higher in SG (Table 1).

Table 1. The affected regions in patients with OMCs associated or not with chronic viral hepatitis B and C.

Parametres	Study Group (n=53)		Control Group (n=56)		χ^2 , p
	abs.	%	abs.	%	
Lip mucosa	33	62,3	21	37,5	6,680; <0,05
Buccal mucosa	39	73,6	37	66,1	0,728; =0,394
Retromolar region	32	60,4	21	37,5	5,705; <0,05
Dorsa surface of the tongue mucosa	13	24,5	7	12,5	2,630; =0,105
Lateral surfaces of the tongue mucosa	25	47,2	17	30,4	3,250; =0,072
Buccal floor mucosa	1	1,9	6	10,7	3,531; =0,061
Hard palate	6	11,3	3	5,4	1,278; =0,259
Soft palate and uvula	2	3,8	3	5,4	0,156; =0,693
Gingiva	10	18,9	8	14,3	0,415; 0,520
Pharyngeal mucosa	1	1,9	1	1,8	0,002; =0,969
1 affected OM site	4	7,5	14	25,0	6,016; <0,05
2 affected OM sites	11	20,8	24	42,9	6,102; <0,05
3 affected OM sites	25	47,2	13	23,2	6,881; <0,01
4-6 affected OM sites	13	24,5	5	8,9	4,806; <0,05

In patients with OMCs, the recurrence rate at 3 months post-treatment showed an increasing trend in SG (7.9%; 95% CI: 2.3-19.6 and 2.4%; 95% CI: 0.3-10.6; $p > 0.05$), which did not reach a statistical significance. However, at 6 months, this parameter was statistically significantly higher in SG (54.8%; 95% CI: 37.5-71.3 and 18.9%; 95% CI: 8.9-33.6; $p < 0.01$) (Figure 4).

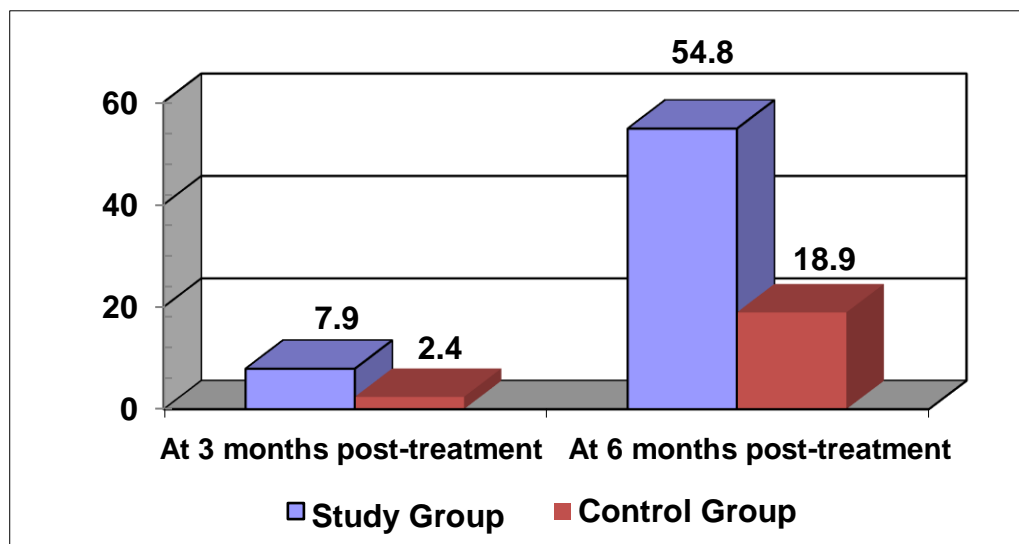


Figure 4. Recurrence rates in patients with oral mucosal conditions (%)

The increase in recurrence rates of OMCs in patients from SG significantly worsened the clinical presentation (symptoms, OM epithelialization) statistically at 6 months post-treatment. Although no statistically significant differences between the study groups were found, by the end of treatment, patients from CG showed lower frequencies of OM involvement in different regions, fewer concurrent affected OM regions, types of OMLs, and number of concurrent OMLs compared to those in SG. Moreover, the absence rate of OMLs and the frequencies of both non-significant and significant OML epithelialization were higher.

3.5. Clinical characteristics of oral lichen planus

The study included 57 patients aged 18 years and older with OLP (mean age 57.04 ± 11.8 ; Md – 58.0, IQR: 52.0-64.5 years old), including 10 males (17.5%; 95% CI: 9.4-28.9) and 47 females (82.5%; 95% CI: 71.1-90.6). The prevalence of OLP was significantly higher in patients with HCV compared to those with HBV (22 cases - 50.0%; 95% CI: 27.2-72.8 vs. 6 cases - 19.4%; 95% CI: 10.8-31.0, respectively; $p < 0.01$).

Regarding the number of OMLs, 16 patients (28.1%; 95% CI: 17.7-40.6) had 1 lesion, 19 patients (33.3%; 95% CI: 22.2-46.2) had 2 lesions, 17 patients (29.8%; 95% CI: 19.2-42.5) had 3 lesions, and 5 patients (8.8%; 95% CI: 3.4-18.2) had 4 lesions. The most commonly affected OML regions were the buccal mucosa in 49 patients (86.0%; 95% CI: 75.3-93.1), the retromolar area in 47 patients (82.5%; 95% CI: 71.1-90.6), the lip mucosa in 22 patients (38.6%; 95% CI: 26.8-51.5), and the lateral surfaces of the tongue mucosa in 22 patients (38.6%; 95% CI: 26.8-51.5) (Figure 5).

The prevalent clinical forms of OLP included reticular (77.2%; 95% CI: 57.1-90.8) (Figure 6 A, B), erosive (52.6%; 95% CI: 39.8-65.2) (Figure 6 C, D, E, F), plaque-like (31.6%; 95% CI:

20.7-44.3) (Figure 7 A, B, C, D), and erythematous ones (10.5%; 95% CI: 4.5-20.4) (Figure 7 E, F, G).

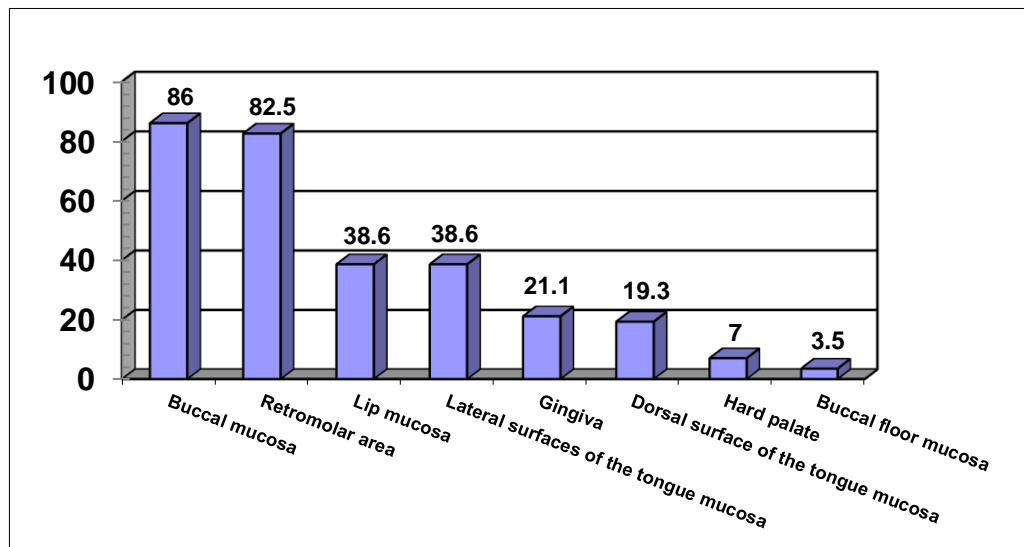


Figure 5. Distribution of patients with oral lichen planus based on the affected regions of the oral mucosa (%)

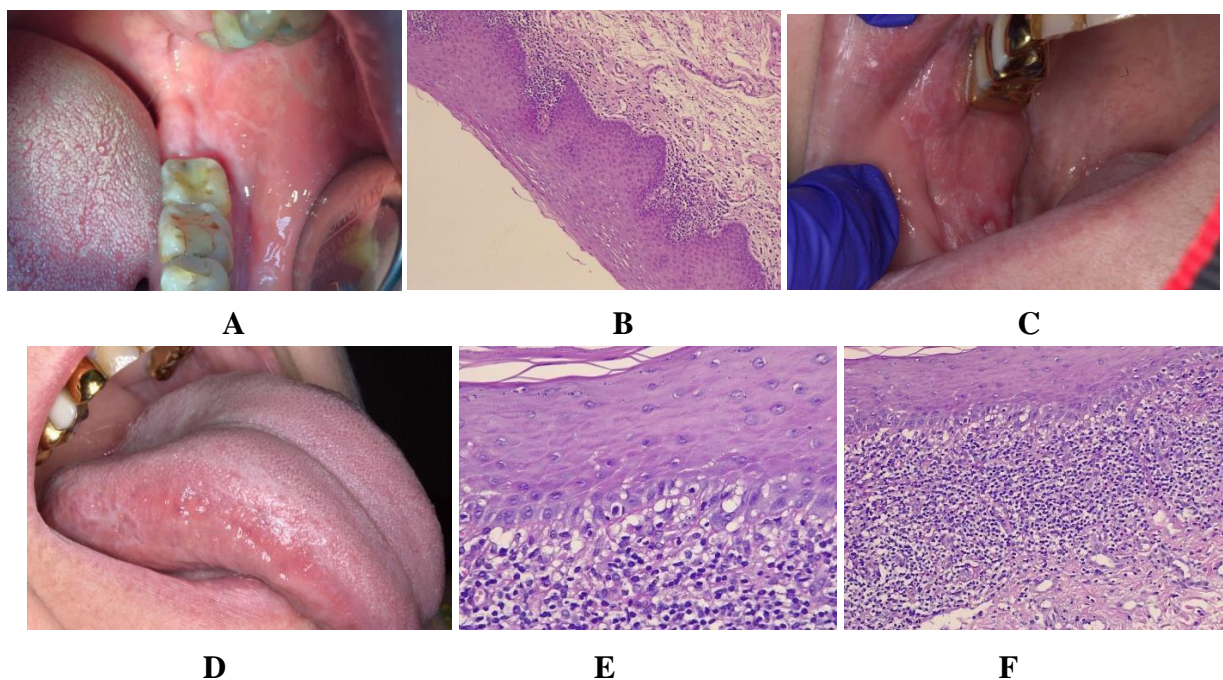


Figure 6. Oral lichen planus of reticular form, involving the buccal mucosa and retromolar area (A); on histopathological examination: small biopsy specimen lined by benign squamous epithelium with orthokeratosis, focal glycogenated squamous cells, adjacent intact basal membrane of the epithelial layer, focal-dispersed chronic inflammatory subepithelial infiltrate, and identified fungal colonies (B). Oral lichen planus of erosive form within bilateral retro-molar region, being of reticular form on lateral surfaces of the tongue (C, D); on histopathological examination: small biopsy specimen showing benign squamous epithelium with parakeratinization and uneven hypergranulosis, basal layer degeneration with presence of occasional apoptotic bodies known as "Civatte bodies," uneven epidermal hyperplasia with serrated epithelial contours (E, F).

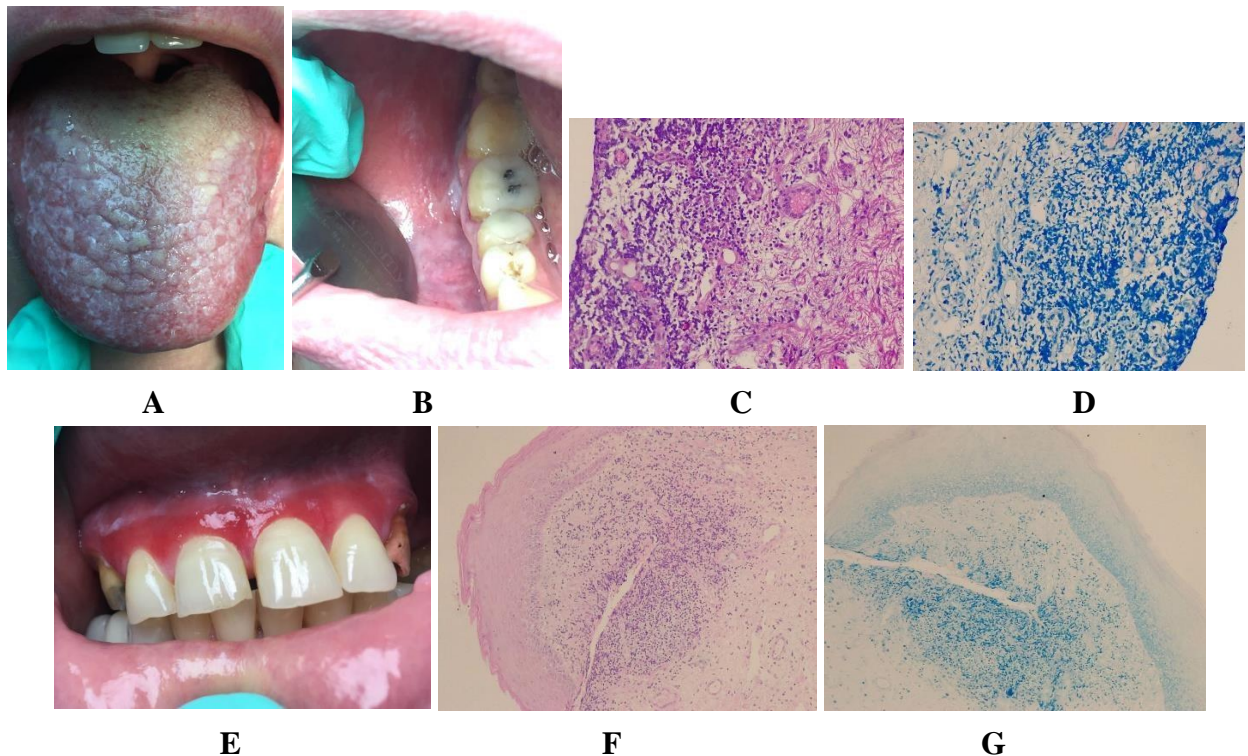


Figure 7. Oral lichen planus, plaque-like form, on the dorsal surface of the tongue and in the bilateral retromolar area (A, B); on histopathological examination: small biopsy fragment showing benign squamous epithelium with marked hyperkeratosis, ulcerative focus with marked lymphoplasmacytic infiltrate, degeneration of the basal layer with presence of occasional Civatte-type apoptotic bodies, serrated epithelial outline, and identified fungal colonies (C, D). Oral lichen planus, of erythematous form, in the gingival area of the upper jaw (E); on histopathological examination: tissue fragment lined with benign squamous epithelium, nonspecific stromal reaction and uneven hypergranulosis, ulcerative focus with marked chronic inflammatory infiltrate in the ulcerated area and in the focus with preserved epithelium, aggregates of epithelioid macrophages, identified bacterial and fungal colonies, uneven basal layer degeneration, and mild subepithelial fibrous proliferation (F, G).

Many patients with OLP exhibited combinations of different clinical forms, viz. a single form of OLP was identified in 45.6% (95% CI: 33.2-58.5) of cases, 2 concurrent forms in 35.1% (95% CI: 23.7-48.0), and 3 concurrent forms in 19.3% (95% CI: 10.7-30.9).

Dynamic assessment at 2 weeks and 3 months of patients' follow-up revealed significant outcomes, such as improvement in clinical presentation, reduction in affected OML regions, epithelialization, and decreased rates of OMLs, as well as an increase in healthy OM areas. However, an increased recurrence rate of OLP (4.3%; 95% CI: 0.9-13.2 at 3 months and 40.0%; 95% CI: 26.7-54.6 at 6 months post-treatment) led to higher frequencies of affected OM regions, number of OM lesioned areas, and type and number of OMLs at 6-month follow-up.

SYNTHESIS OF RESULTS OBTAINED

The research conducted across various geographic regions worldwide and on different patient samples assessed the OMCs and diagnosed the following: oral candidiasis (2.7-17.58%), mucosal vitiligo (15.38%), burning mouth syndrome (11.0%), viral ulcer (9.6%), OSCC (8.9%), recurrent aphthous ulcer (7.69-8.1%), labial herpes (6.59%), cheilitis (6.58%), OLP (3.9-12.08%), pemphigus vulgaris (5.49%), submucosal oral fibrosis (4.2-26.8%), leukoplakia (3.29-18.3%),

toxic epidermal necrolysis (3.29%), systemic lupus erythematosus (3.29%), and papilloma (1.5-2.1%) [13, 14].

The patients' assessment enrolled in the present study revealed the prevalence of OMCs as follows, ranked in descending order: OLP in 38.0% of cases, burning mouth syndrome in 21.3%, recurrent chronic aphthous stomatitis in 16.7%, oral candidiasis in 11.3%, mucosal vitiligo in 5.3%, acute or chronic herpetic stomatitis in 4.0%, leukoplakia of the OML in 4.0%, exudative polymorphous erythema in 3.3%, benign oral tumors in 3.3%, and oral neoplastic diseases in 2.0% of cases.

Based on study findings, 87-91% of patients diagnosed with oral mucosal lesions presented with a single lesion, while 9-13% exhibited 2 or more concurrent lesions. The most common site of these lesions was the buccal mucosa (46.0%), followed by the labial mucosa (17.5%), the buccal vestibule (15.0%), the tongue (13.0%), the gingiva (3.5%), the hard palate (3.0%), and the buccal floor (2.0%). A recent study confirmed these findings, where lesions most commonly involved the oral mucosa (50.0%), anterior two-thirds of the tongue (34.3%), hard palate (7.0%), retromolar fossa (3.9%), gingival mucosa (2.3%), buccal floor (1.5%), and lips (0.7%) [13].

These results align with those obtained in our study cohort, viz. 88.7% of patients presented with a single condition and 11.3% had 2 concurrent conditions. The most affected regions were the buccal mucosa (69.7%), labial mucosa (49.5%), retromolar region (48.6%), lateral surfaces of the tongue (38.5%), dorsal surface of the tongue (18.3%), gingiva (16.5%), hard palate (8.3%), buccal floor mucosa (6.4%), soft palate and uvula (4.6%), and pharyngeal mucosa (1.8%).

The study found no association between incidence of HCV infection and oral lesions, consistent with other case-control studies, particularly in regions with a low prevalence of HCV infection [1, 7].

The present study data are also consistent with most previous researches on OLP concerning the location of lesions, clinical presentation, chronicity, symptoms, and medical history.

Based on a review of the literature and our findings, a diagnostic protocol for OML in patients with chronic viral hepatitis B and C was developed (Figure 8).

A monitoring program was subsequently created to detect early mucosal changes in the oral cavity associated with chronic viral hepatitis B and C, evaluate and monitor the progression of OML conditions, and prevent complications in this patient cohort, which includes:

1. Consultation, involving initial assessment of the oral mucosa condition following the diagnosis of chronic viral hepatitis; documentation of medical history; identification of risk factors and other associated conditions.
2. Periodic check-ups to timely assess the oral mucosa at set intervals (2 weeks, 3 months, and 6 months post-treatment); examination of the oral mucosa to identify signs of inflammation, ulcerative lesions, or other changes.
3. Additional investigations to periodically assess liver function and overall health; to conduct oral mucosal biopsies for suspicious lesions to provide diagnostic and histological information.
4. Education and Counseling to provide detailed information to the patient regarding oral mucosal conditions associated with chronic viral hepatitis, as well as outlining the importance of proper oral hygiene; to advise the patient on a healthy lifestyle and eliminating risk factors that may worsen these diseases.
5. Interdisciplinary collaboration includes working with a multidisciplinary medical team to assess and effectively manage chronic viral hepatitis and its associated oral mucosal

conditions. This involves consulting and cooperating with specialists in dentistry and other relevant fields for complex or challenging cases.

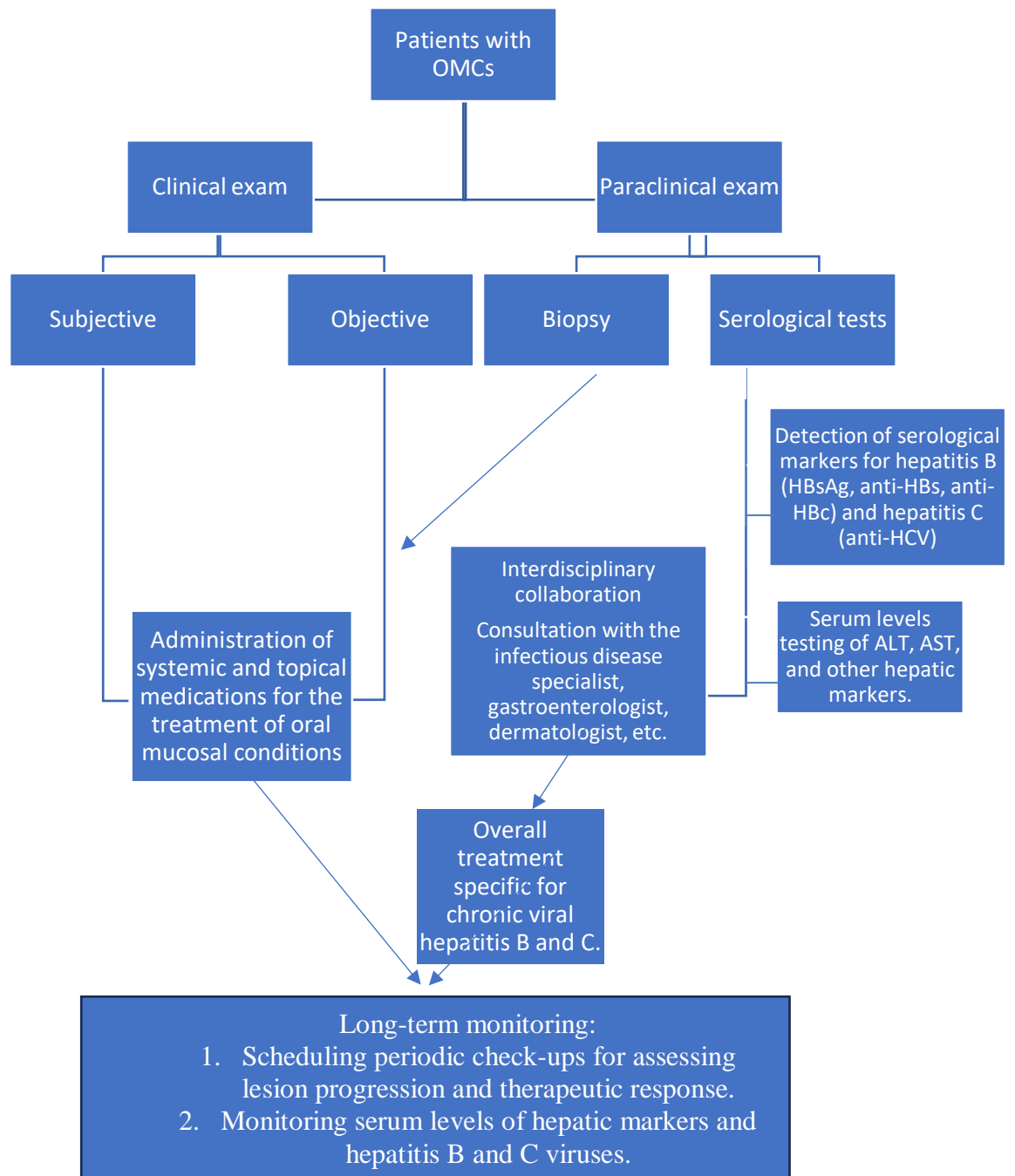


Figure 8. Protocol for diagnosing oral mucosa conditions in patients with chronic viral hepatitis B and C

GENERAL CONCLUSIONS

1. Following the analysis of the oral mucosa involvement on the underlying chronic viral hepatitis B and C revealed no statistically significant differences between the two research groups ($p>0.05$).
2. The development of a diagnostic protocol for oral mucosal conditions in patients with chronic viral hepatitis B and C significantly improved the management of these complex medical conditions through interdisciplinary collaboration.
3. Comparing the obtained results revealed that patients in the study group had a concomitantly higher number of affected regions: the rates of involvement of 1 region of the oral mucosa (7.5% and 25.0%, respectively; $p<0.05$) and 2 regions of the oral mucosa (20.8% and 42.9%, respectively; $p<0.05$) were statistically significantly higher in the control group with oral mucosal conditions without chronic viral hepatitis B and C. However, the rates of involvement of 3 regions of the oral mucosa (47.2% and 23.2%, respectively; $p<0.01$) and 4 to 6 regions of the oral mucosa (24.5% and 8.9%, respectively; $p<0.05$) were statistically significantly higher in the main group with oral mucosal conditions associated with chronic viral hepatitis B and C.
4. Establishing effective therapeutic approaches, combining local and systemic treatments through interdisciplinary collaboration, is essential for enhancing the quality of life and clinical outcomes of patients with chronic viral hepatitis B and C and associated oral mucosal conditions.
5. Among patients with oral mucosal conditions, there was an increasing tendency in the recurrence rates at 3 months post-treatment in the study group (7.9% and 2.4%, respectively; $p>0.05$), although the statistical significance was not reached. At 6 months post-treatment, the recurrence rate significantly increased in the study group (54.8% and 18.9%, respectively; $p<0.01$), prompting the development of a monitoring and prevention program for oral mucosal conditions in chronic viral hepatitis B and C patients which is composed of consultation, periodic check-ups, additional investigations, education and counselling and interdisciplinary collaboration.

PRACTICAL RECOMMENDATIONS

1. A detailed and standardized protocol has been developed for assessing oral mucosal conditions in patients with chronic viral hepatitis B and C.
2. It is recommended to use serological and molecular tests to detect hepatitis B and C viruses.
3. Evaluating serum levels of inflammatory markers and liver function helps correlate oral mucosal conditions with hepatitis status.
4. Training dental practitioners to conduct thorough oral mucosal examinations will enhance the detection of oral mucosa lesions, the monitoring of oral conditions, particularly potential malignant oral mucosa disorders.
5. Recording and photographing oral lesions will facilitate monitoring the progression of oral diseases.
6. The developed monitoring program will provide an accurate tracking of oral conditions, thus implementing effective preventive measures to reduce the further risks of occurrence and flare-ups of oral diseases in this category of patients.

REFERENCES

1. Abou-bakr A, Khalil E. Oral conditions in hepatitis c virus-infected Egyptian patients: a case-control study. *Egypt Dent J.* 2020; 66(4): 2339-2344.
2. Adnane S, Mahad C, Haitami S, Yahya I. Hepatitis C virus infection and oral lichen planus: A controversial association. *Adv Oral Maxillofac Surg.* 2022; 6: 100271.
3. Akhlaq H, Khan M, Nasir M, Sheikh H, Mehmood N, Sajjad I. Prevalence and Risk Factors of Oral Mucosal Lesions: A Retrospective Study of Patients Attending Oral Diagnosis Department of Siohs Karachi, Pakistan. *PJMHS.* 2021; 15(11): 3273-3278.
4. Cheng Y, Gould A, Kurago Z, Fantasia J, Muller S. Diagnosis of oral lichen planus: a position paper of the American Academy of Oral and Maxillofacial Pathology. *Oral Surg Oral Med Oral Pathol Oral Radiol.* 2016; 122(3): 332-354.
5. Gangeshetty N, Kumar B. Oral lichenplanus: Etiology, pathogenesis, diagnosis, and management. *World J Stomatol.* 2015; 4(1): 12-21.
6. Gheorghe D, Foia L, Toma V, Surdu A, Herascu E, Popescu D et al. Hepatitis C Infection and Periodontal Disease: Is there a Common Immunological Link? *J Immunol Res.* 2018; 2018: 8720101.
7. Ismail R, Elansary A, Ezzatt O, Hamed M, Gamil Y. Hepatitis C associated oral lesions: A hospitalbased retrospective case control study in Egypt. *J Int Oral Health.* 2023; 15: 52-58.
8. Jin L, Lamster I, Greenspan J, Pitts N, Scully C, Warnakulasuriya S. Global burden of oral diseases: emerging concepts, management and interplay with systemic health. *Oral Dis.* 2016; 22(7): 609-619.
9. Nishat R, Jaiswal M, Kumari N, Jha P, Bhuyan L, Vinayam D. A Study on Prevalence of Oral Mucosal Lesions in the Geriatric Population of Eastern India. *Annals R.S.C.B.* 2021; 25(1): 6772-6785.
10. *Oral Potentially Malignant Disorders: Healthcare Professional Training (1st edition).* London, 2022. 120 p.
11. Sulka A, Simon K, Piszko P, Kalecińska E, Dominiak M. Oral mucosa alterations in chronic hepatitis and cirrhosis due to HBV or HCV infection. GIRSO. https://www.researchgate.net/publication/6167523_Oral_mucosa_alterations_in_chronic_hepatitis_and_cirrhosis_due_to_HBV_or_HCV_infection [accesat la 02.08.2023].
12. *Supravegherea epidemiologică a hepatitelor virale B, C și D, măsurile de control și răspuns, anul 2022.* 2023 <https://ansp.md/wp-content/uploads/2023/05/Supravegherea-epidemiologica-a-hepatitelor-virale.pdf>
13. Tripathy S, Gupta P, Jain A, Chatterji P. Prevalence of oral mucosal lesions in a tertiary care centre: one-year prospective study. *Int J Otorhinolaryngol Head Neck Surg.* 2020; 6: 1704-1708.
14. Yao H, Zhang Q, Song Q, Liu M, Tang G. Characteristics of Oral Mucosal Lesions and Their Association With Socioeconomic Status and Systemic Health: A Cross-Sectional Study of Consecutively Collected Oral Medicine Clinic Data in a Remote Rural Area of China. *Front Public Health.* 2022; 10: 897814.

LIST OF PH.D. THESIS-RELATED PUBLICATIONS

Dr. Irina Ivasiuc, a Ph.D. graduate from the School of Medical Sciences, completed the Ph.D. thesis on “**Assessment of Oral Mucosal Conditions in Patients with Chronic Viral Hepatitis B and C**” at the Department of Dental Propaedeutics “Pavel Godoroja”, within Nicolae Testemitanu State University of Medicine and Pharmacy, Republic of Moldova, 323 - Dentistry.

SCIENTIFIC PUBLICATIONS

- **Articles published in international scientific journals:**
 - ✓ **Articles in ISI, SCOPUS, and other international databases**
 - 1. Golburean O, Hagen M. H., Uncuța D., Tighineanu M., Manrikyan G., Vardanian I., Andresen C., Singh B., Porosencova T., **Ivasiuc I.**, Cheptanaru O., Markaryan M., Shakavets N., Sapkota D., Sjøland T. M., Costea D. E., Özkaya F. Knowledge, opinions, and practices related to oral cancer prevention and oral mucosal examination among dentists in Moldova, Belarus and Armenia: a multi-country cross-sectional study. In: *BMC Oral Health*. 2021, nr. 1(21), pp. 1-10. ISSN 1472-6831. DOI: 10.1186/s12903-021-02011-2 (**IF: 3.747**)
 - 2. **Ivasiuc I.**, Moritoi T., Brinza D., Melnic E., Uncuța D. Common oral mucosal lesions in patients with or without chronic viral hepatitis. In: *Oral Surgery, Oral Medicine, Oral Pathology and Oral Radiology*. Volume 132, Issue 1, July 2021, Page e22, DOI:<https://doi.org/10.1016/j.oooo.2021.03.090> (**IF: 2.538**)
 - **Articles in national scientific journals:**
 - ✓ **articles in category B journals**
 - 3. **Ivasiuc I.**, Markaryan M., Markaryan G., Shacavets N., Levco S., Markaryan M., Vardanyan I., Marițoi T., Cheptanaru O., Costea D. E., Uncuța D. Aspecte clinicomorfofopatologice ale lichenului plan oral. In: *Buletinul Academiei de Științe a Moldovei. Științe Medicale*. 2022, nr. 3(74), pp. 212-215. ISSN 1857-0011. DOI: 10.52692/18570011.2022.3-74.42
 - 4. **Ivasiuc I.**, Melnic E., Costea D.E., Uncuța D., Oral lichen planus – an oral potentially malignant disorder (OPMD) of the oral cavity. In: *Moldovan Journal of Health Sciences*. 2024, 11(1), pp. 58-65. ISSN 2345-1467. DOI: 10.52645/MJHS.2024.1.09
 - ✓ **articles in category C journals**
 - 5. Buiuc E., Uncuța D., **Ivasiuc I.** Tratatamentul fluorozei dentare cu tehnici miniinvazive. In: *Medicina Stomatologică*, 2021, nr. 3(59), pp. 91-95. ISSN 1857-1328. DOI: 10.53530/1857-1328.21.59.13
- **Abstracts/summaries/theses in national and international scientific conference papers**
 - 6. **Ivasiuc I.**, Uncuța D., Cheptanaru O., Melnic S. Incidența afecțiunilor mucoasei bucale la pacienții cu hepatite cronice virale pe plan mondial. In: *Medicina Stomatologică*, 2016, nr. 3(40), pp. 97-98. ISSN 1857-1328.0

7. **Ivasiuc I.** General aspects of diagnosis of oral mucosal diseases of the patients with chronic viral hepatitis B and C. In: *Abstract book The 7th International Medical Congress for Students and Young Doctors MedEspera*. Chişinău, 2018, pp. 224-225. ISBN 978-9975-47-174-9.
 8. Maniuc O., **Ivasiuc I.** Fordyce granules in oral medicine. In: *MedEspera: International Medical Congress for Students and Young Doctors*. Chişinău. 2020, p. 339. ISBN 9789975-151-11-5.
 9. Brînză D., Măriţoi T., **Ivasiuc I.**, Mândruţa-Stratan R., Uncuţa D. Expresia markerilor biologici în leziunile premaligne ale carcinomului de cap şi gât. In: *Congresul consacrat aniversării a 75-a de la fondarea Universităţii de Stat de Medicină şi Farmacie „Nicolae Testemiţanu”*. Chişinău, 2020, p. 695.
 10. **Ivasiuc I.**, Uncuţa D., Cernega V. Eficiency of photodynamic therapy in periodontal disease. In: *International Student Medical Congress*, Ed. 8th edition, Košice, Slovakia. 2016, p. 203.
 11. Cernega V., **Ivasiuc I.**, Bujor N., Hîncu S. Photodynamic therapy in periodontal disease. In: *International Congress of Medical Sciences*, Ed. 15th edition, Sofia, Bulgaria. 2017, p. 299.
 12. Cheptanaru O., Bajurea N., Uncuţa D., Melnic S., Poştaru C., **Ivasiuc I.**, Chele N. Reabilitarea implanto-protetică a edentaţiei unidentare în zona frontală. In: *Medicina Stomatologică*. Chişinău, 2016, pp. 92-93. ISSN 1857-1328.
 13. Maniuc, O., **Ivasiuc I.**, Trifan D., Uncuţa D. Diagnosis and treatment of moderate decay in permanent teeth. *Revista de Ştiinţe ale Sănătăţii din Moldova*, 2022, nr. 3 An.1(29), p. 537. ISSN 2345-1467.
 14. Melnic S., Motelica G., Cheptanaru O., Poştaru C., **Ivasiuc I.**, Chele N. Conceptele încărcării implantelor dentare. In: *Medicina Stomatologică*, 2016, nr. 3(40), pp. 91-92. ISSN 1857-1328.
 15. Nistreanu D., Cheptanaru O., Trifan D., Calitca M., **Ivasiuc I.**, Uncuţa D. Treatment of dental caries with light cure composite materials. In: *The 37th Balkan Medical Week: “Perspectives Of The Balkan Medicine In The Post-COVID-19 Era” & The 8th Congress Of Urology, Dialysis And Kidney Transplant From The Republic Of Moldova With International Participation: “New Horizons In Urology”*. Chişinău, 2023, p. 295.
 16. Trifan D., **Ivasiuc I.**, Calitca M., Uncuţa D. Use of calcium silicate Materials in direct pulp capping in permanent teeth. In: *The 37th Balkan Medical Week: “Perspectives Of The Balkan Medicine In The Post-COVID-19 Era” & The 8th Congress Of Urology, Dialysis And Kidney Transplant From The Republic Of Moldova With International Participation: “New Horizons In Urology”*. Chişinău, 2023, p. 292.
- **Patents, patent certificates, registration certificates, materials at invention exhibitions:**
 17. Spînu C., Pînzaru I., Sajin O., Spînu I., Isac M., Miron A., Roşca A., **Ivasiuc I.**, Pântea V. Metodă de diagnostic al hepatitei virale B la persoane cu expunere accidentală. Brevet de invenţie de scurtă durată MD 1245 Z 2018.12.31

- **Participations with presentations at scientific forums:**

- ✓ **international**

18. Uncuța D., Costea D. E., **Ivasiuc I.** Заболевания слизистой оболочки полости рта. Диагноз и биопсия. *XXIX Международный онлайн симпозиум «Инновационные технологии в стоматологии»*, г. Омск, 3-4 марта 2021.

- ✓ **national**

19. **Ivasiuc I.**, Uncuța D., Markaryan M., Markaryan G., Shacavets N., Costea D. E. Aspecte clinico-morfopatologice ale lichenului plan oral. *Conferința științifică națională cu participare internațională dedicată membrului de onoare al AÇM, profesorului universitar, Ilustru chirurg Constantin ȚÎBÎRNĂ, fondator al chirurgiei naționale “Chirurgia personalizată la adulți și copii – chirurgia viitorului”*, Chișinău, 24-25 martie 2022.

20. **Ivasiuc I.**, Uncuța D., Zănoagă O., Levco S., Cheptanaru O., Manrikyan M., Costea D. E. Diagnosticul și tratamentul granulomului piogen. Cazuri clinice. *Conferința științifică națională cu participare internațională dedicată membrului de onoare al AÇM, profesorului universitar, Ilustru chirurg Constantin ȚÎBÎRNĂ, fondator al chirurgiei naționale “Chirurgia personalizată la adulți și copii – chirurgia viitorului”*, Chișinău, 24-25 martie 2022.

21. Uncuța D., Porosencova T., Cheptanaru O., Melnic S., **Ivasiuc I.** Ultrasunetul în afecțiunile parodontiului. *Conferința științifică anuală consacrată aniversării a 90-a de la nașterea ilustrului medic și savant Nicolae Testemițanu*, Chișinău, 16-20 octombrie 2017.

22. Uncuța D., **Ivasiuc I.**, Stepco E. Unele afecțiuni ale mucoasei cavității bucale. *Conferința științifică anuală consacrată aniversării a 90-a de la nașterea ilustrului medic și savant Nicolae Testemițanu*, Chișinău, 16-20 octombrie 2017.

23. Uncuța D., Porosencova T., **Ivasiuc I.**, Trifan D. Utilizarea tehnologiilor digitale în parodontologie, odontologie, endodonție și medicină orală. *Conferința științifică “Tehnologii Digitale în Stomatologia Multidisciplinară”*, Chișinău, 09-10 Septembrie 2023.

24. Uncuța D. Porosencova T., Cheptanaru O., Melnic S., **Ivasiuc I.**, Poștaru C., Trifan D. Remedii în igienă orală în stomatologie. *Conferința Consacrată Zilei Stomatologului Sfintei Apolonia și Comemorarea Academicianului, Profesor universitar, Doctor habilitat, Ion Lupan*, Chișinău, 9 februarie 2018.

- **Poster participation at scientific forums:**

- ✓ **international**

25. **Ivasiuc I.**, Uncuța D., Cernega V. Eficiency of photodynamic therapy in periodontal disease, *International Student Medical Congress*, Ed. 8th edition, Košice, Slovakia. 2016.

26. Cernega V., **Ivasiuc I.**, Bujor N., Hîncu S. Photodynamic therapy in periodontal disease, *International Congress of Medical Sciences*, Ed. 15th edition, Sofia, Bulgaria. 2017.

27. Trifan D., **Ivasiuc I.**, Calitca M., Uncuța D. Single visit direct pulp capping with mineral trioxide aggregate, *XII International Scientific and Practical Conference «Priorities of pharmacy and dentistry: from theory to practice» is dedicated to the 70th anniversary of professor Omarova Roza Amirzhanovna*, Almaty, Kazakstan, 16 noiembrie 2023.

✓ **national**

28. **Ivasiuc I.**, Uncuța D., Cheptanaru O., Melnic S. Incidența afecțiunilor mucoasei bucale la pacienții cu hepatite cronice virale pe plan mondial. *XVIII-lea congres Național cu participare Internațională al Asociației Stomatologilor din Republica Moldova*. Chișinău, 20-21 octombrie 2016.
29. **Ivasiuc I.**, Uncuța D., Cheptanaru O., Melnic S. Incidența afecțiunilor mucoasei bucale la pacienții cu hepatite cronice virale pe plan mondial. *Conferința științifică anuală în cadrul Zilelor USMF „Nicolae Testemițanu”*. Chișinău, 18-21 octombrie 2016.
30. **Ivasiuc I.**, Cheptanaru O., Melnic S., Uncuța D. Biopsia în afecțiunile mucoasei bucale. *Conferința științifică anuală în cadrul Zilelor USMF „Nicolae Testemițanu”*. Chișinău, 18-19 octombrie 2018.
31. Maniuc O., **Ivasiuc I.**, Uncuța D. Fordyce granules in oral medicine. *MedEspera 2020, the 8th International Medical Congress for Students and Young Doctors*. Chisinau, september 24-26, 2020.
32. Costea D. E., Merete Sølrand T., Uncuța D., Melnic E., Spinei A., **Ivasiuc I.**, Brînza D., Mărițoi T. Afecțiunile mucoasei cavității bucale – biopsie, diagnostic și supraveghere, workshop, *Congresul consacrat aniversării a 75-a de la fondarea USMF “Nicolae Testemițanu”*, 21-23 octombrie 2020, p.95.

ADNOTARE

Ivasiuc Irina

„Evaluarea afecțiunilor mucoasei cavității bucale la pacienți cu hepatite cronice virale B și C”

Structura tezei. Lucrarea este expusă pe 123 pagini de text digital, constă din introducere, 3 capitole, sinteza rezultatelor obținute, concluzii generale, recomandări practice și indice bibliografic cu 242 de referințe. Materialul ilustrativ include 18 figuri, 25 de tabele, 1 formulă statistică și 7 anexe. subiectul tezei au fost publicate 32 de lucrări științifice, inclusiv 1 articol fără coautori, 5 articole în ediții recenzate, inclusiv 2 articole în reviste cu factor de impact.

Cuvinte-cheie: afecțiuni ale mucoasei cavității orale, lichen plan, lichen plan oral, hepatita virală cronică B, hepatita virală cronică C, virusul hepatitei B, virusul hepatitei C, manifestări extrahepatice.

Scopul cercetării: analiza multidimensională a afecțiunilor mucoasei cavității orale în asociere cu hepatitele virale cronice B și C și elaborarea unui plan optim de tratament profilactic și de monitorizare în dinamică a acestor pacienți.

Obiectivele cercetării: Elucidarea implicațiilor afecțiunilor mucoasei cavității orale pe fundal de hepatite virale cronice B și C. Elaborarea unui protocol de diagnostic aplicabil pentru cazurile de afecțiuni ale mucoasei cavității orale la pacienții cu hepatite virale cronice B și C la diverse etape de observare clinică cu și fără hepatită. Compararea rezultatelor obținute la diagnosticarea afecțiunilor mucoasei cavității orale în lotul de pacienți cu hepatite virale cronice B și C cu cel fără hepatite. Stabilirea conduitei terapeutice a afecțiunilor mucoasei cavității orale la pacienții cu hepatite virale cronice B și C. Elaborarea programului de monitorizare și profilaxie a afecțiunilor mucoasei cavității orale la pacienți cu hepatite virale cronice B și C.

Noutatea și originalitatea științifică: Au fost evidențiate particularitățile de diagnostic, clinice și histopatologice la pacienții cu maladii ale MCO și cu HVB și HVC. Au fost evidențiați markerii specifici hepatitelor virale cronice B și C la pacienții cu AMCO.

Problema științifică soluționată: problema diagnosticului precoce ale AMCO și a hepatitelor virale constituie până în prezent o problemă clinică și științifică. În urma studiului efectuat s-a demonstrat că pacienții diagnosticați cu HVB sau HCV dezvoltă forme mai severe ale afecțiunilor MCO. Monitorizarea și evaluarea în timp a acestui grup de pacienți a arătat scăderea ratelor de recidive și prevenirea dezvoltării formelor grave ale AMCO.

Semnificația teoretică a studiului: Rezultatele studiului vor aprofunda și fundamenta particularitățile manifestărilor clinice la pacienții cu AMCO asociate cu HVB și HVC. A fost determinată conduita terapeutică și elucidate implicațiile AMCO la pacienții cu HVB și HVC la diverse etape de supraveghere clinică.

Valoarea aplicativă a lucrării: elaborarea și implementarea în practica medicală a unui protocol de diagnostic pentru AMCO la pacienții cu HVB și HVC. Implementarea acestui protocol în practica medicală va permite diagnosticarea mai rapidă a pacienților, reducerea ratei de avansare a AMCO la bolnavii cu hepatite virale cronice, ameliorarea rezultatelor tratamentului cu un efect economic, determinat de reducerea numărului de recidive ale bolii și a duratei incapacității temporare de muncă.

Implementarea rezultatelor științifice: Cercetările au fost realizate în Clinica stomatologică universitară și Clinica stomatologică „Dia Dents”. Examenul histomorfologic al specimenelor de biopsie, prelevate din mucoasa orală, a fost efectuat în cadrul Catedrei de morfopatologie a Facultății de Medicină nr. 2 a Instituției Publice Universitatea de Stat de Medicină și Farmacie “Nicolae Testemițanu”.

АННОТАЦИЯ

Ивасюк Ирина

«Оценка поражений слизистой оболочки полости рта у пациентов с хроническими вирусными гепатитами В и С»

Структура диссертации. Работа изложена на 123 страницах цифрового текста, состоит из введения, 3 глав, обобщения полученных результатов, общих выводов, практических рекомендаций и библиографического указателя с 242 источниками. Иллюстративный материал включает 18 рисунков, 25 таблиц, 1 статистическую формулу и 7 приложений. По теме диссертации опубликованы 32 научные работы, в том числе 1 статья без соавторов, 5 статей в рецензируемых изданиях, включая 2 статьи в журналах с импакт-фактором.

Ключевые слова: поражения слизистой оболочки полости рта, красный плоский лишай, оральный плоский лишай, хронический вирусный гепатит В, хронический вирусный гепатит С, вирус гепатита В, вирус гепатита С, внепеченочные проявления.

Цель исследования: многомерный анализ поражений слизистой оболочки полости рта (ПСОПР) в ассоциации с хроническими вирусными гепатитами В и С (ХВГВ и ХВГС) и разработка оптимального профилактического плана лечения и динамического мониторинга этих пациентов.

Задачи исследования: Выяснение последствий поражений ПСОПР на фоне хронических вирусных гепатитов В и С. Разработка диагностического протокола, применимого для случаев ПСОПР у пациентов с ХВГВ и ХВГС на различных этапах клинического наблюдения с гепатитом и без него. Сравнение результатов диагностики ПСОПР у пациентов с ХВГВ и ХВГС с результатами у пациентов без гепатитов. Определение терапевтической тактики лечения ПСОПР у пациентов с ХВГВ и ХВГС. Разработка программы мониторинга и профилактики ПСОПР у пациентов с ХВГВ и ХВГС.

Научная новизна и оригинальность: Выявлены особенности диагностики, клинические и гистопатологические характеристики у пациентов с ПСОПР и ХВГВ и ХВГС. Определены специфические маркеры ХВГВ и ХВГС у пациентов с ПСОПР.

Решенная научная проблема: Проблема ранней диагностики ПСОПР и вирусных гепатитов до сих пор является клинической и научной проблемой. В результате проведенного исследования было доказано, что пациенты, диагностированные с ХВГВ или ХВГС, развивают более тяжелые формы заболеваний слизистой оболочки полости рта. Мониторинг и оценка состояния этой группы пациентов показали снижение частоты рецидивов и предотвращение развития тяжелых форм ПСОПР.

Теоретическое значение исследования: Результаты исследования углубляют и обосновывают особенности клинических проявлений у пациентов с ПСОПР, ассоциированных с ХВГВ и ХВГС. Определена терапевтическая тактика и выявлены последствия ПСОПР у пациентов с ХВГВ и ХВГС на различных этапах клинического наблюдения.

Практическая ценность работы: разработка и внедрение в медицинскую практику диагностического протокола для ПСОПР у пациентов с ХВГВ и ХВГС. Внедрение этого протокола в медицинскую практику позволит ускорить диагностику пациентов, снизить скорость прогрессирования ПСОПР у больных с хроническими вирусными гепатитами, улучшить результаты лечения с экономическим эффектом за счёт уменьшения количества рецидивов заболевания и продолжительности временной нетрудоспособности.

Внедрение научных результатов: Исследования были проведены в Университетской стоматологической клинике и стоматологической клинике "Dia Dents". Гистоморфологическое исследование биопсийных образцов, взятых из слизистой оболочки полости рта, было проведено на кафедре морфопатологии факультета медицины №2 Государственного университета медицины и фармации им. "Николае Тестемицану".

ANNOTATION

Ivasiuc Irina

“Assessment of oral mucosal lesions in patients with chronic viral hepatitis B and C“

Thesis structure. The paper is presented on 123 pages of digital text, consisting of an introduction, 3 chapters, a synthesis of the obtained results, general conclusions, practical recommendations, and a bibliographic index with 242 references. The illustrative material includes 18 figures, 25 tables, 1 statistical formula, and 7 appendices. The topic of the thesis has led to the publication of 32 scientific works, including 1 article without co-authors, 5 articles in peer-reviewed journals, including 2 articles in journals with an impact factor.

Keywords: oral mucosal lesions, lichen planus, oral lichen planus, chronic viral hepatitis B, chronic viral hepatitis C, hepatitis B virus, hepatitis C virus, extrahepatic manifestations.

Research aim: A multidimensional analysis of oral mucosal lesions associated with chronic viral hepatitis B and C, and the development of an optimal prophylactic treatment plan and dynamic monitoring of these patients.

Research objectives: To elucidate the implications of oral mucosal lesions in the context of chronic viral hepatitis B and C. To develop an applicable diagnostic protocol for cases of oral mucosal lesions in patients with chronic viral hepatitis B and C at various stages of clinical observation, both with and without hepatitis. To compare the diagnostic results of oral mucosal lesions in a group of patients with chronic viral hepatitis B and C with those without hepatitis. To establish the therapeutic approach for oral mucosal lesions in patients with chronic viral hepatitis B and C. To develop a monitoring and prevention program for oral mucosal lesions in patients with chronic viral hepatitis B and C.

Scientific novelty and originality: The diagnostic, clinical, and histopathological characteristics of patients with oral mucosal lesions (OML) and chronic viral hepatitis B (HBV) and C (HCV) have been highlighted. Specific markers for chronic viral hepatitis B and C in patients with OML have been identified.

Resolved scientific problem: The issue of early diagnosis of oral mucosal conditions (AMCO) and viral hepatitis remains both a clinical and scientific challenge. The study demonstrated that patients diagnosed with HBV or HCV develop more severe forms of oral mucosal conditions. Continuous monitoring and evaluation of this group of patients showed a decrease in recurrence rates and the prevention of severe forms of AMCO.

Theoretical significance of the study: The results of the study will deepen and substantiate the particularities of clinical manifestations in patients with OML associated with HBV and HCV. The therapeutic approach has been determined, and the implications of OML in patients with HBV and HCV at various stages of clinical supervision have been elucidated.

Practical Value of the Work: The development and implementation of a diagnostic protocol for OML in patients with HBV and HCV in medical practice. The implementation of this protocol in medical practice will allow for faster diagnosis of patients, reduce the progression rate of OML in patients with chronic viral hepatitis, improve treatment outcomes, and provide an economic benefit by reducing the recurrence rate of the disease and the duration of temporary work incapacity.

Implementation of Scientific Results: The research was conducted at the University Dental Clinic and the "Dia Dents" Dental Clinic. The histomorphological examination of biopsy specimens taken from the oral mucosa was performed in the Department of Morphopathology of the Faculty of Medicine No. 2 at the Public Institution "Nicolae Testemițanu" State University of Medicine and Pharmacy.

IVASIUC Irina
ASSESSMENT OF ORAL MUCOSAL LESSIONS IN PATIENTS WITH CHRONIC
VIRAL HEPATITIS B AND C

323.01 – Dentistry

Summary of the Ph.D. thesis in Medical Sciences

Approved for printing:

Paper size: 60x84 1/16

Offset paper. Offset printing.

Print run: copies.

Print sheets:

Order No.
