

Doctoral School in Medical Sciences

Manuscript title:

UDC: [616.62-007.271-02:616.65-002-036.12]-072.1(043.2)

COLȚA Artur

**ENDOUROLOGICAL TREATMENT OF INFRAVESICAL
OBSTRUCTION CAUSED BY CHRONIC NONBACTERIAL
PROSTATITIS CONSEQUENCES**

321.22 – UROLOGY AND ANDROLOGY

Summary of Ph.D. Thesis in Medical Sciences

The present Ph.D thesis has been developed at the Chair of Urology and Surgical Nephrology, PI "Nicolae Testemitanu" State University of Medicine and Pharmacy ,based on the PMHI "Timofei Moşneaga" Republican Clinical Hospital of the founding Consortium of the Doctoral School Studies in Medical Sciences.

Scientific advisor

Ghicavii Vitalii,

Dr.habil. in Medicine, Assoc. Prof

Members of the steering committee:

Tănase Adrian,

Dr.habil. in Medicine, Univ. Prof

Bernic Jana,

Dr.habil. in Medicine, Univ. Prof.

Vişnevschi Anatolie,

Dr.habil. in Medicine, Univ. Prof

Ph.D. thesis defense will take place on at 28.06.2023, 02.00 pm., within "Nicolae Testemitanu" State University of Medicine and Pharmacy, on Bd Ştefan cel Mare şi Sfânt, office 205 during the meeting of the Commission for Public Doctoral Thesis Defence, approved by the decision of the Scientific Council of the Consortium on 29.03.2023 (minute no. 3).

The members of the Commission for Public Ph.D thesis defence:

President:

Ceban Emil,

Dr.habil. in Medicine, Univ. Prof

Corresponding member of AMS

Scientific secretary:

Dumbrăveanu Ion,

Dr.habil. in Medicine, Assoc. Prof

Members:

Ghicavii Vitalii,

Dr.habil. in Medicine, Assoc. Prof

Cazacov Vladimir,

Dr.habil. in Medicine, Univ. Prof

Official Reviewers:

Bernic Jana,

Dr.habil. in Medicine, Univ. Prof

Bumbu Gheorghe,

Univ.Prof, from Romania

Axenti Alin

Ph.D in Medicine

Author:

Colţa Artur

CONTENTS

The research conceptual framework	4
Ph.D. Thesis content	10
1. Clinical manifestations and surgical management of infravesical obstruction caused by complications of chronic nonbacterial prostatitis.....	10
2. Material and research methods	10
2.1. Overall characteristics of patient groups included in the clinical trial	10
2.2. Clinical and paraclinical examination and selection of patients with obstructive infravesical micturition disorders.....	12
2.3. Laboratory and instrumental investigations	12
2.4. Methods of surgical treatment for chronic nonbacterial prostatitis and its consequences	13
2.5. Data statistical analysis	15
3. Clinical manifestations and endourological treatment outcomes of infravesical obstruction induced by sclerosing chronic nonbacterial prostatitis	15
3.1. Comparative analysis of the transurethral endoscopic treatment outcomes for infravesical obstruction in sclerosing chronic nonbacterial prostatitis.....	19
3.2. Characteristics of intra- and postoperative complications and assessment of the effectiveness of transurethral endoscopic treatment of infravesical obstruction in sclerosing chronic nonbacterial prostatitis	21
4. Surgical endoscopy interventions used in differentiated treatment of calculous chronic nonbacterial prostatitis. The comparative analysis of the obtained results and treatment complications of prostatitis.....	22
5. Synthesis of the obtained results	27
General conclusions	29
Practical recommendations	30
Selective bibliography	31
List of scientific papers published on the topic	32
Annotations (in Romanian, Russian, English)	34

LIST OF ABBREVIATIONS

BNS – bladder neck sclerosis	LUT - lower urinary tract
BPH – benign prostatic hyperplasia	LUTS – lower urinary tract symptoms
CNBP – chronic abacterial prostatitis	NIDDK – National Institute of Diabetes and Digestive and Kidney Diseases
CP – prostatic calculus NIH – US National Institutes of Health	NIH-CPSI - international prostatitis symptom scale (score)
DRE - digital rectal examination	NOS - nitric oxide synthase
Ho:YAG – Holmium laser	PSA – prostate-specific antigen
HoLEP – Holmium laser enucleation of prostate	TRUSP – transrectal ultrasound of the prostate
QoL –quality of life	UB – urinary bladder
iNOS – Inducible nitric oxide synthase	UUT – upper urinary tract
IPSS – international prostatic symptom scale (score)	
SOD – superoxide dismutase	

THE CONCEPTUAL RESEARCH FRAMEWORK

The relevance and importance of the researched issue.

Infravesical obstruction (IVO) is a general concept that includes a number of urological diseases, characterized by voiding dysfunction, difficulty urinating, urinary retention and other types of dysuria due to an obstruction present in the bladder neck area and urethra. IVO is a polyetiologiological pathological process characterized by lower urinary tract symptoms. IVO is also a symptom for a range of diseases, including BPH, prostate cancer, bladder cancer, bladder neck sclerosis, chronic prostatitis (prostatic sclerosis and calculi), urethral strictures and obliteration, etc. [1, 2].

Prostatitis is the most common urological disease among the male population under 50 years of age and the third most common urological diagnosis in older men following prostate adenoma and prostate cancer, whereas the mean age of a patient with prostatitis is 43 years. Symptoms of prostatitis are present in 10-40% of men and cause a significant decrease in the patients 'quality. According to urologists [3, 4], 9% of men per general population suffer from prostatitis. Of the total male population, 2-12% of males aged over 20 may have symptoms specific to prostatitis, and about 9-16% of men are diagnosed throughout their lives. Depending on the disease length since the symptom onset, prostatitis can be acute, when it started recently, or chronic, when symptoms persist for more than 3 months [5].

Chronic prostatitis (CP) is the most common and challenging to diagnose androurological disease, ranking first among inflammatory diseases of the genitourinary system in men and first among men's diseases per general population [5]. The age range of patients with chronic prostatitis varies from 18 to 80 years, including more than 50% of men under the age of 40-50 years, although, the number of men over 60 years is also increasing. In modern urology, chronic prostatitis remains a very common inflammatory disease, poorly understood and very difficult to treat. It mainly affects young men and those of reproductive age, often accompanied by impaired copulative and generative functions [6, 7]. Since the disease affects the most working-able and reproductive male population, aged between 20 -40, with an incidence of up to 35-40%, it is both an issue of medical and great social importance [8], thus requiring an increasing efficiency in diagnosis and treatment of chronic prostatitis [5, 9, 10]. Among problems associated with this condition, the urination disorders are the most relevant and debatable. It may result due to inadequate treatment of acute prostatitis, though most common chronic prostatites develop as primary chronic conditions on the underlying prostatic obstruction, characterized by slow progression of chronic inflammatory processes that lead to sclerotic scarring changes in the prostate.

There are various morphopathological classifications of CP, particularly, the catarrhal prostatitis (with damage of the acinar excretory ducts), follicular (with the involvement of separate prostatic lobes), and interstitial or parenchymal (with total organ damage) prostatitis. Chronic prostatitis is characterized by the formation of dilated cavities in the follicular system due to the blockage of their channels and stasis of the prostatic secretion. A long-term chronic prostatitis can lead to sclerosis of the organ, followed by a decrease in the size of the prostate and the development of infravesical obstruction [2, 4, 11, 12, 13].

Currently, the most commonly accepted classification of prostatitis worldwide is that proposed by the US National Institutes of Health (NIH) [8], which includes the following types: acute bacterial prostatitis; chronic bacterial prostatitis (chronic inflammation of the prostate tissue and the presence of uropathogens detected in 5-10% of patients); chronic nonbacterial prostatitis / chronic pelvic pain syndrome (a non-infectious type, detected in 90-95% of patients) and asymptomatic inflammatory prostatitis (being histologically confirmed with no clinical manifestations). According to this classification, there are two types of chronic nonbacterial prostatitis/chronic pelvic pain syndrome (CNBP/CPPS): inflammatory CNBP/CPPS III A and non-inflammatory CNBP/CPPS III B [2, 8, 14].

According to the US NIH definition [15, 16], nonbacterial "chronic prostatitis" also includes the chronic pelvic pain syndrome in the region of the small pelvis, perineum, and in the genitals for at least 3 months, with or no inflammatory response in the prostatic tissues, however no pathogens are detected in the prostatic tissues, prostatic secretion, seminal fluid and urine, with the presence (or lack) of obstructive or irritating symptoms of micturition disorder; positive (or negative) findings of the bacteriological investigations.

The CP manifestations are multiple and varied, the course of the disease can be monosymptomatic and, in rare cases, latent [8, 17]. It is emphasized that the clinical picture of chronic prostatitis is characterized by a triad of syndromes: pain, dysuria and sexual dysfunction.

The etiology, pathogenesis and pathophysiology of chronic nonbacterial prostatitis (CNBP) have been insufficiently studied. Since there is no single, convincing and evidence-based etiological factor, CNBP is currently considered as a multifactorial condition in which patients have concomitant psychopathological disorders of sexual and reproductive function. Non-bacterial syndromes are caused by immunological, neuroendocrine, inflammatory factors and occur in a genetically and anatomically susceptible population.

Chronic nonbacterial prostatitis refers to diseases that develop on the underlying proteolytic dysregulation in blood flow and prostate. The activation of proteolysis plays a key role in inflammation. The coordinated action of proteases and their inhibitors helps in maintaining the body homeostasis, a sequence of complex and multicomponent responses, considered as a universal nonspecific response to inflammation.

Currently, there are no clinically valid diagnostic criteria to differentiate between inflammatory (category III A) and non-inflammatory (category III B) CNBP/CPPS. Thus, determining the role of NO [12, 14, 19, 20], oxidative stress, and the kallikrein-kinin system is of particular interest in the pathogenesis and diagnosis of CNBP/CPPS.

A specific and extremely difficult task is the treatment of prostate cancer [7, 18, 19], which shows an extremely low cure rate. The treatment commonly depends on the category and symptomatology of the patient [21, 22]. There are many specialized literature sources [13, 17] describing various schemes and methods of treating prostate cancer. Treatment of patients with CP should be a comprehensive one and involve all the etiology and pathogenesis features of the disease [21].

The rapid development of endourology has made it possible to use endoscopic methods in the diagnosis and treatment of a number of urological diseases of both the upper and lower urinary tract. The high efficiency and low traumatization have made it possible to expand the indications for their use, whereas in some situations these have become the methods of choice in the treatment of a number of urological conditions and their complications.

The first descriptions in the treatment of chronic bacterial prostatitis by transurethral electroresection (transurethral prostatectomy) (TURP) were described by MEARES E.M. and STAMI T.A. [1968], while the nonbacterial by SMART C.J. and JENKINS K.D. [1975]. Later on, based on the deep analysis of this issue, it was determined that a detailed approach is important in the diagnosis and selection of the candidates for surgical intervention, since the anatomical and morphological features of the prostate, as well as the urodynamic condition of lower urinary tract (severe histological changes, infravesical obstructive syndrome or their various combinations) should be thoroughly studied. Despite the multiple studies carried out regarding this issue, the etiopathogenesis, early diagnosis, prevention and treatment of urination disorders in patients with chronic prostatitis, manifested by sclerosing changes in the prostate tissue (prostate sclerosis), the formation of prostatic calculi (calculous prostatitis or prostatolithiasis) [7] are still underconsidered. It is believed that patients with chronic prostatitis and voiding disorders, as well as those presenting IVO symptoms should be first suspected for complications of prostate sclerosis, prostate calculi, etc., [5, 7].

Thus, transurethral endoscopic surgery of prostatitis and its outcomes is justified by the presence of resistant and relapsing forms of this disease in patients, in which conservative methods of treatment are ineffective.

The aforementioned methods of transurethral surgical treatment are more often required in the third stage of the disease, otherwise irreversible, viz. in prostate sclerosis or in build-up of stones (calculi) - prostatolithiasis.

Prostate sclerosis (73%) is one of the final stages of a chronic inflammatory process in the prostate [12]. This stage is typically characterized by a reduced inflammatory response, whereas the organ is significantly replaced by scarring connective tissue [23, 24].

The assessment of the surgical outcomes for prostate sclerosis in patients and the subsequent improvement in the patients' urodynamic parameters allowed L.M. GORILOVSKY and M.M. DOBROKHOTOV [23], V. GHICAVÎI [24] to conclude that transurethral resection is an effective treatment for infravesical obstruction, which helps in restoring urinary continence, especially in elderly and senile patients, as well as improving their quality of life.

Chronic calculous prostatitis is often detected by accident in various parts of the parenchyma while examining patients with lower urinary tract symptoms. These appear as persistent opacities, usually interpreted as prostatic calculi, thus the pathology is poorly understood by clinical practitioners. The exact prevalence of prostatic calculi is not well known yet, with 7% to 70% of cases reported rates, since most cases of prostate stones are asymptomatic and have an asymptomatic evolution.

The causative factors leading to calculi formation in the prostate are still understudied. It is generally accepted that prostatic calculi might result from aging in older men. It is assumed that the prostate calculus is formed by sedimentation of the prostatic secretion and calcification of amylocytes in long-term inflammatory process, as well intraprostatic reflux if a urinary obstruction is present (prostatic adenoma, urethral stricture, etc.), thus resulting in clinical prostatitis. Hence, in most cases, prostate calculi can be considered a consequence of chronic prostatitis [23].

Another issue to consider is the time, namely the proper timing for managing prostatic calculi. Patients with independent uncomplicated prostatic calculi do not need special treatment. Most authors recommend that if no prostatic calculi-related complications are present, periodic patient's condition follow-up should be carried out. Patients with prostatic calculi on the underlying chronic prostatitis require conservative anti-inflammatory treatment. In patients with an intractable infection or in whom prostate stones are associated with BPH or may perforate the prostatic urethra causing urinary retention or protrude into the urethra and cause urinary tract obstruction, may require transurethral endoscopic resection, which should improve the symptoms, though the intervention does not guarantee the removal of all calculi, nor does it exclude the possibility of their formation further on. Deep removal of prostatic calculi is also a treatment option for chronic bacterial inflammation of the prostate due to bacterial contamination, being a source of persistent inflammation, leading to prostate abscess or malignancy. In these cases, prostatic stones can be easily removed using a transurethral electroresection loop or other minimally invasive methods. The transurethral procedure is the method of choice in calculi removal, particularly in young patients, in order to preserve sexual function. In elderly patients, an open prostaticolithotomy is performed for a single large stone or a group of stones [25]. However, it should be noted that currently there are few studies related to infravesical obstruction in complications of chronic nonbacterial prostatitis and their exclusion by transurethral endoscopic interventions. For these reasons, all of the above-mentioned issues, including the urinary dysregulations in patients with chronic nonbacterial prostatitis, remain relevant and require additional further research.

Research hypothesis

The main research idea was to study the possible mechanisms of development of scarring and sclerotic, as well as calculous complications in patients with CP and to develop principles for their early diagnosis based on the results obtained, as well as outline some preventive and treatment options for possible subsequent IVO occurrence. Based on this concept, the purpose and objectives of the present study were determined.

The **purpose of the research** is to determine the diagnostic options of chronic nonbacterial prostatitis, its most frequent complications and the effectiveness of transurethral endourological differential treatment of infravesical obstructions caused by the corresponding prostatitis.

To achieve the research purpose, the following **research objectives** were set:

1. To study the incidence and structure of IVO resulting from CNBP complications.
2. To determine the possibilities of use and efficacy assessment of transurethral endoscopic interventions in IOV, caused by CNBP and its complications.
3. To conduct a comparative study on the incidence and severity of intra- and postoperative complications following transurethral endoscopic interventions (TURP, ITUP, LASER), as well as developing comprehensive actions aimed at reducing them in the treatment of IVO, caused by sclerosis and calculous CP.
4. Based on the clinical and morphological data, to determine the peculiarities and reasonable indications of the differentiated treatment of obstructive complications in CNBP.
5. To justify the methods for recovery of the infravesical permeability of the prostatic urethra in patients with sclerosing and calculous prostatitis, as well as to determine their effectiveness.
6. To determine the need and capacity of entomotherapy in order to prevent and minimize intra- and postoperative complications of surgical interventions in obstructive CNBP.

The scientific novelty of the research

The article is a comprehensive study conducted at the Department of Urology and Surgical Nephrology of Nicolae Testemitanu SUMPh and within the Urology Clinic of the IMPH Timofei Moshneaga Republican Clinical Hospital, on transurethral endoscopic treatment outcomes of IVO resulting from complications of chronic nonbacterial prostatitis and depending on the sclerotic and lithiasis manifestations of the prostate.

Based on the obtained clinical data, a comparative and multilateral analysis was carried out for the first time on the urodynamic outcomes, possible intra- and postoperative complications, as well as on the effectiveness of various transurethral endoscopic treatment options (transurethral electroresection and laser resection) in patients with chronic obstructive nonbacterial prostatitis.

The incidence and structure of infravesical obstruction due to chronic nonbacterial prostatitis complications were comparatively studied based on clinical data obtained, viz. prostate sclerosis was found in 62% of cases, calculous prostatitis- in 38% of cases; the possibility of using transurethral endoscopic interventions was justified, as well as their therapeutic effectiveness in restoring the urethral infravesical passage in patients with IVO associated with prostatic sclerosis and lithiasis; indications for differentiated treatment of obstructive consequences of chronic nonbacterial prostatitis were also clarified, contributing to a decrease in the frequency and severity of complication incidence following the interventions; the causes of intra- and postoperative complications of transurethral resection (TURP and laser) were also studied in this category of patients.

It was found that a relatively lower frequency of complications due to transurethral endoscopic interventions in IVO, caused by CNBP are incomparable with the advantages of these methods, such as high information content, therapeutic possibilities and technical simplicity, minimal invasiveness, high tolerance in patients, reduced treatment and rehabilitation costs, as well as the possibility of undergoing treatment repeatedly in case of recurrent diseases or complications with no further increased risk to the patient or the organ.

The entomotherapy efficacy has been proved by administering anti-inflammatory, antiproliferative and antifibrotic drugs for chronic nonbacterial prostatitis in order to reduce the sclerotic and calculous consequences, which greatly contributes to the prevention and minimization of intra- and postoperative complications following transurethral endourological interventions.

Laser treatment technique has also been justified by showing the effectiveness and safety of these interventions in patients with sclerosis and calculi-associated chronic nonbacterial prostatitis, being manifested by a rapid recovery of urinary continence, as well as by justifying the appropriateness of the use of these interventions in all categories of patients.

The scientific problem solved in the thesis

IVO caused by the CNBP complications, such as post-inflammatory sclerosis of the prostate and calculous prostatitis, requires a differentiated and adequate selection of transurethral endoscopic treatment options, based on the clinical and morphological condition (the predominance of the sclerotic process or calculi formation), as well as on the possibility of minimizing the intra- and postoperative complications in case of undergoing any of them.

Previous drug therapy of chronic nonbacterial prostatitis using the entomological anti-inflammatory, antiproliferative and antifibrotic preparations improves the manifestations of sclerotic processes and prostatic lithiasis and, consequently, significantly reduces the possible complications of transurethral endoscopic interventions, used in IVO caused by CNBP. In calculi-related chronic nonbacterial prostatitis, transurethral endoscopic procedure can be applied by transurethral incision or resection and laser, depending on the size, consistency and location of the prostatic calculi. These actions will contribute to right decision-making in the development of the treatment plan and the selection of method of choice for infravesical obstructive urological diseases, including complicated CNBP.

Theoretical significance and applied value of the research

The present research has implemented the methodology for examining and assessing patients with CNBP by determining the proteolytic processes and the biochemical inflammatory markers involved in the development of CNBP/CPPS, by identifying the clinically reliable diagnostic criteria for differentiating between inflammatory and non-inflammatory variants of CNBP. Indications for using minimally invasive transurethral endoscopic methods in the treatment of CNBP consequences have also been optimized. New transurethral endoscopic methods for the treatment of IVO due to CNBP complications have been introduced, depending on the size, volume, localization, duration and etiology of prostatic sclerosis and calculi in patients, including the elderly and senile patients. The differentiated use of transurethral endoscopic interventions implemented in the treatment of this urological pathology contributed to their extensive application, which have improved the treatment outcomes, and thus reducing the hospital and rehabilitation length of the patient. Based on the data analysis obtained following the endoscopic treatment, indications and contraindications for various methods (TUR, laser) and an algorithm for the treatment of patients with infravesical obstruction were established. Moreover, a decrease in the incidence of possible complications, depending on the nature of sclerosing or calculous tissue, has also been recorded in this category of patients.

Also, there has been developed and further used in practice a treatment method for the patients with sclerosing and calculous CNBP via transurethral laser resection, which is an alternative to endoscopic treatment of prostatolithiasis, showing highly effective outcomes and a lower complication rate. Depending on evidence-based indications and contraindications, there were established criteria for selecting appropriate patients for this type of treatment, as well as postoperative management approaches. Technical aspects of performing surgical interventions and methods for preventing possible complications were also determined.

There were outlined the particular features of using various methods of transurethral resection (electrovaporization and laser) in the treatment of IVO due to CNBP complications,

which contribute to an increase in the treatment effectiveness, decreased postoperative risks, and a reduced number of complications. The proposed indications and contraindications for the use of transurethral resection of the prostate can improve the treatment outcomes in IVO, associated with CNBP and its complications, improve the patients' quality of life in the postoperative period, and reduce the hospital stay length of patients after the intervention.

An effective preventive measure against CNBP complications was suggested, which is based on entomological preparations associated with several minimally invasive transurethral endoscopic interventions. Endoscopic transurethral resection (TUR and laser) has proved to restore adequate micturition in most of patients with CNBP-related IVO.

Implementation of scientific results

The obtained scientific research results were implemented within the Department of Urology and Surgical Nephrology of the "Nicolae Testemițanu" State University of Medicine and Pharmacy in the teaching-training process of undergraduate students, in postgraduate training of resident- urologists and in ongoing medical education of specialists, as well as in the clinical activity of the Urology and Endourology Department of PHMI "Timofei Moșneaga" Republican Hospital and within the Urology units of the municipal and district PHMIs from the Republic of Moldova.

Approval of thesis research results

The thesis-related research materials and results were presented at the following national and international scientific forums:

- The VII Congress of Urology, Dialysis and Renal Transplant from the Republic of Moldova with international participation (Chisinau, 2019);
- The International Medical Congress of students and young doctors "MedEspera", Chisinau, 8th edition, 2020; 9th edition, 2022;
- The Congress of Oncologists from the Republic of Moldova with international participation, the 5th edition "Cancer prevention and control - a constant challenge", dedicated to the 60th anniversary from the foundation of the PHMI Oncological Institute of the Republic of Moldova (Chisinau, 2020);
- The Anniversary conference "Гражданин, учёный, педагог" ("Grazhdanin, uchjonyj, pedagog") - 90 years since the birth of Professor A.D. Myasnikov, KGMU, (Kursk, 2020);
- The XXVIII National Congress of Russia "Человек и лекарство" ("Chelovek i lekarstvo") (Moscow, 2021);
- The XXI Congress of the Society of Urologists of Russia (Sankt-Petersburg (online), September, 2021);
- The Meetings of the Scientific Society of Urologists from the Republic of Moldova (Chisinau, 2019; 2020; 2021; 2022);
- Specialized international exhibitions, salons and competitions in Chisinau (2021), Iași (2021; 2022), Cluj-Napoca (2021; 2022), Timișoara (2021), Sibiu (2022) and others;
- The University Days and Annual Scientific Conference on "Research in biomedicine and health: quality, excellence and performance" of PI "Nicolae Testemițanu" SUMPh (Chisinau, 2020, 2021; 2022).

The Ph.D. thesis was discussed, approved and recommended for defence at a joint meeting of the members of the guiding group, scientific advisor and of Chair of Urology and Surgical Nephrology of the Nicolae Testemițanu SUMPh (minute no. 4, dated on November 30, 2022) and at the meeting of the Scientific Seminar 321, and General Medicine Specialties: 321.13- Surgery, 321.14-Pediatric Surgery, and 321.22 -Urology and Andrology (minutes No. 1 of February 8, 2023).

22 scientific articles were published on the Ph.D. topic, including 5 publications with no co-authorship and 10 publications in peer-reviewed publications, 2 articles and abstracts in

international journals, abstracts and communications in collections of international (5) and national (2) scientific conferences. There were developed 6 acts for the implementation of the scientific results (Appendix 2), 2 invention patents (MD 1526; MD 1527) and 1 certificate of copyright registration (Series O No. 7287) (Appendix 3), 6 medals, of which 4 gold, 1 silver, 1 bronze and the AGPI cup "The best invention created by a young inventor" Infoinvent, 2021.

The Ph.D. thesis received a positive conclusion from the Research Ethics Committee within the "Nicolae Testemitanu" State University of Medicine and Pharmacy (minutes No. 17 of 12/11/2019).

Key words: prostatic lithiasis, calculi, prostate, prostatitis, treatment, prostatic sclerosis, chronic prostatitis, transurethral resection, prostaticolithiasis, infravesical obstruction, laser, holmium enucleation.

The volume and structure of the thesis

The Ph.D. thesis is written in Romanian as a manuscript on 133 printed pages, including 38 figures, 17 tables, 5 appendices, annotations in Romanian, Russian and English, introduction, and five chapters, which consist of the literature review, research materials and methods, personal results and their synthesis, general conclusions, practical recommendations, and a list of 222 of bibliographic references.

PH.D. THESIS CONTENT

1. CLINICAL MANIFESTATIONS AND SURGICAL MANAGEMENT OF INFRAVESICAL OBSTRUCTION CAUSED BY COMPLICATIONS OF CHRONIC NONBACTERIAL PROSTATITIS

This chapter provides a specialized literature review and the latest data regarding IVO due to CNBP and its complications, such as: chronic sclerosing and calculous prostatitis, the etiopathogenesis of these disorders, theories of prostatic calculi occurrence, modern diagnostic and treatment methods, including transurethral minimally invasive endoscopy. The specialized literature describes the success rates associated with the endoscopic treatment of prostaticolithiasis and sclerosing nonbacterial prostatitis, the advantages and disadvantages of treatment procedures, occurrence of complications, their management and patient behavior following a minimally invasive transurethral endoscopic treatment. Furthermore, it also describes the actions provided after the diagnosis of CNBP complications has been confirmed, as well as the customized treatment approach used to minimize the risk of complications, based on clinical investigations obtained.

The specialized literature analysis highlighted the need for a comparative deep research into the study of the effectiveness and safety of possible endoscopic transurethral treatment methods used in CNBP-related complications, as well as in the development of the new principles in differentiated treatment.

The characteristics of some transurethral endoscopic treatment methods, mainly based on recent literature data, allowed clarifying the prospects for the introduction and differentiated use of various therapeutic means and their subsequent study in CNBP-related complications, with or without being combined with medication (conservative treatment) and surgical treatment.

2. MATERIAL AND RESEARCH METHODS

2.1. Overall characteristics of patient groups included in the clinical trial

The present research is based on 149 patient's examination materials, diagnosed with IVO due to CNBP III A and III B and its complications, namely chronic sclerosing and calculous prostatitis. The general (main) study group accounted for 100% of urological patients, who were initially consulted and then admitted to the department of Urology and Endourology of the PHMI

“Timofei Mosneaga” Republican Clinical Hospital, which is the clinical base of the Department of Urology and Surgical Nephrology of the Nicolae Testemitanu SUMPh for 4 years now (2019-2022). The study also included the survey data of the long-term follow-up of patients, which provided the benchmarks for a multidimensional analytical study.

The inclusion criteria. The study involved: men aged > 27 years, diagnosed with a IVO caused by CNBP, followed by sclerotic changes in the prostate, prostate calculi, calculous prostatitis, and post-inflammatory prostatitis, confirmed clinically and paraclinically, as well as radiologically and intraoperatively during the surgical procedure.

The exclusion criteria. The anomalies and tumors of the bladder, prostate and other LUT organs were excluded from the study, as well as patients with CNBP, neurological diseases and dysfunctions causing neurogenic bladder disorders, underlying autoimmune disorders, including patient’s history, severe comorbidities or critical conditions that could interfere with the evolutionary follow-up of the patients under study.

The study group was selected in accordance with the etiopathogenetic classification of IVO and the aforementioned conditions, which led to infravesical urodynamic disorders due to complications of prior treatment (Table 1).

Table 1. Distribution of patients with IVO according to their age and condition

Age (years)	Number of patients	Number of patients with		
		Chronic prostatitis	Prostatic sclerosis	Calculous prostatitis
27-30	10 (6.71%)	10 (6.71%)	-	-
31-40	28 (18.8%)	13 (8.72%)	5 (3.35%)	10 (6.7%)
41-50	59 (39.6%)	11 (7.38%)	35 (23.4%)	13 (8.72%)
51-70	52 (34.8%)	9 (6.08%)	26 (17.4%)	17 (11.4%)
Total	149 (100%)	43 (28.8%)	66 (44.2%)	40 (26.8%)

The distribution of patients according to the triggering conditions of infravesical obstruction based on type of intervention is shown in Table 2.

Table 2. Distribution of patients according to the conditions and type of transurethral endoscopic treatment

Disorders (total – 106 patients)	Type of transurethral endoscopic surgical treatment	
	transurethral incision and resection (TUR)	Laser resection
Prostate sclerosis (n = 66 de patients)	30 (28.3 %)	36 (33.9 %)
Calculous prostatitis (n = 40 de patients)	10 (9.4 %)	30 (28.3 %)

Thus, group I included 43 patients with CNBP/chronic pelvic pain syndrome (CPPS) (Table 1) with or without urinary disorders (IVO) who underwent standard conservative drug treatment, of which 33 patients additionally used adenoprosin, an entomological rectal suppository (150 mg), whereas 10 men were included within the control study group (not treated with adenoprosin).

The study **group II** was selected according to the etiopathogenetic classification of infravesical obstruction and the above-mentioned conditions leading to LUT symptoms. It included 106 patients with chronic sclerosing and calculous prostatitis, which further on developed into infravesical disorders of urodynamics (urinary disorders), and which were examined and treated by transurethral endoscopy (Table 2). The treatment of these obstructive conditions and of their associated complications involved various surgical methods, based on their specific indications and contraindications for the treatment of relevant pathologies, which were traditionally recommended and to some extent optimized, in order to determine their effectiveness and priority, based on the analysis of the postoperative outcomes. Following a detailed examination and diagnostic confirmation of chronic prostatitis with voiding disorders, 2 studied subgroups were created. *Subgroup I* included 66 (62.2%) patients with chronic prostatitis associated with sclerotic changes in the post-inflammatory prostate followed by urination disorders, thus, being treated with various endoscopic transurethral methods. This group also included 6 patients who were previously treated with adenoprosin, but later developed urination

disorders (persistent pain and dysuric syndrome), which also served as an indication for surgical treatment.

Subgroup II included 40 (37.7%) patients aged 31 to 70 years (mean age 49.7 years) with urinary disorders caused by prostate calculi (calculous prostatitis) localized in various gland sites, which were single or multiple, of various sizes and etiology, being also treated via a differentiated transurethral endoscopic approach (laser - 30 patients, TU incision or resection - 10 patients).

2.2. Clinical and paraclinical examination and selection of patients with obstructive infravesical micturition disorders

The examination of patients with IVO due to chronic prostatitis complications at the initial stage (before surgery) included clinical examination and history taking of the course of the disease, the patients' presenting complaints by assessing them via the IPSS scale, clinical manifestations, assessment of the patient's quality of life index (QoL) and, particularly the digital rectal examination. At the initial check-up, the patient underwent the following basic tests: a blood work, a general urinalysis, and assessment of creatinine and blood urea levels. If an acute or chronic infection was suspected during the urinary tract symptoms exacerbation, then the urine culture testing, Nechiporenko urine test, analysis of prostate secretion and urethral smear were performed.

Patients were followed-up postoperatively within the hospital settings, with daily monitoring of the overall and local condition, by completing the IPSS questionnaires regarding the QoL, performing physical examinations if necessary, and repeated bioassays and some imaging studies, namely, the transrectal ultrasound (for determining prostate condition and the residual urine volume) and uroflowmetry. Furthermore, the patients were examined at 1 month, then 3, 6, and 12 months postoperatively. If patients were referred with emerging complaints related to early or late (long-term) complications after surgical treatment of the corresponding pathology, the patient underwent a clinical and paraclinical examination at the time of referral. If late postsurgical complications occurred, these underwent inpatient examination and treatment, if necessary. The criteria for the corresponding pathology recurrence included recurrent obstructive urination phenomena and a decrease in the maximum urine flow velocity $< 10\text{--}12$ ml/s, associated with other specific factors. Thus, a repeated examination or re-intervention to restore normal urination was considered. A mandatory histological examination of the resected prostate tissue was carried out.

2.3. Laboratory and instrumental investigations

All patients, regardless of the surgical approach, underwent planned preoperative examination, according to the protocol and patient's examination file. The complex examination methods used in IVO patients, additionally to routine clinical and laboratory studies, included basic instrumental studies, such as, urethrography, transrectal ultrasound, excretory urography with panoramic rectal cliché, pelvic ultrasound, including bladder and prostate imaging, USG assessment of residual urine, and total PSA.

The diagnosis of CNBP should also be confirmed by examining the prostate secretion (the leukocytes counts and lecithin grains), the inflammatory biochemical markers of the prostate gland (NO content in blood leukocytes, prostatic secretion and ejaculate based on V.A METELISKAYA and N.G. GUMANOV (2005) and adapted by GUDUMAC V. et al. (2012). Undoubtedly, digital rectal examination (moderate pain, consistency, heterogeneous tissue fluctuations (flaccid features) is extremely important for the diagnosis of CP.

Ascending urethrocytography was performed in all patients whose medical history included prior LUT surgery.

The "Mediwatch" Portaflow PA - 00201 and Urostym Laborie Medical Logies - Canada device was used for the urodynamic research. Uroflowmetry was used to evaluate the time of onset of urination; the rise of the curve and the time to reach the maximum urine flow velocity;

the maximum urine flow velocity (Q_{\max}); characteristic curve of urination; the volume of urine excreted (the urination amount); urination time; the mean urine flow rate (Q_{mean}).

Transrectal ultrasound of the prostate gland (TRUS-P) revealed the uneven density of prostatic tissue, with the development of sclerosis due to a decrease in its size, as well as residual urine (infravesical obstruction) often detected in the bladder.

2.4. Methods of surgical treatment for chronic nonbacterial prostatitis and its consequences

The choice of a particular method depends on the localization, type and severity of the condition. Several transurethral endoscopic surgical methods have been developed and used, some of which have been improved, others have been introduced into clinical practice for the first time.

a) Transurethral resection of the prostate

Transurethral electroresection of the prostate (TUR) was performed by taking into account the specifics of the patient population, whereas a special technique was used aimed at the fastest possible intervention timing and minimal risk of bleeding (Fig. 1, 2 and 3). This made it possible to initially remove most of the tissues and carry out safe hemostasis, since the vessels pass through this area.

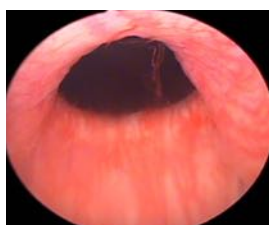


Figure 1. Endoscopic image of prostate sclerosis.

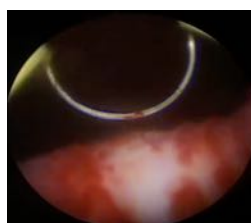


Figure 2. Transurethral electroresection of the prostate in its sclerosis. The resection starts at 5 o'clock of the conventional quadrant.

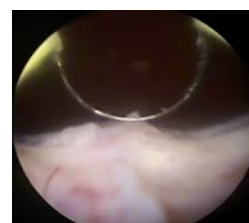


Figure 3. Transurethral electroresection of the prostate in its sclerosis. The prostate tissue was removed at 5 o'clock of the conventional quadrant.

b) Transurethral incision of the prostate

Transurethral incision of the prostate (TUIP) is an alternative surgical technique to endoscopic treatment of subvesical obstruction in younger patients with small prostate adenomas [6, 10] or with chronic prostatitis (Fig. 4). The principle of the technique differs from TURP, viz. the removal of the obstruction by reducing the constructive tone secondary to the incision of the prostate (and not by tissue resection, as in TURP). According to the recommendations of the European Association of Urology, TUIP is indicated in patients with a prostate that does not exceed 30 cm³ (measured by TRUS) (Fig. 5) that lacks a median lobe. The instruments used are the resectoscope or a rigid urethrocystoscope with a 30-degree optic. To perform the incision, any auxiliary tools might be used, allowing to perform this maneuver, namely, the cold blade, a Collings loop, mono- or bipolar resection loops, vaporization electrodes, and laser fibers (Fig. 6), etc.

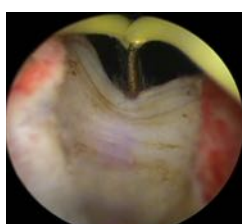


Figure 4. Transurethral incision of the prostate.

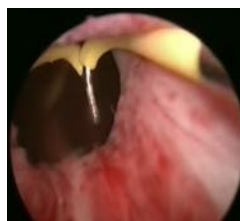

Figure 5. TUIP performed in a young patient with a prostate volume with less than 30 cm³.

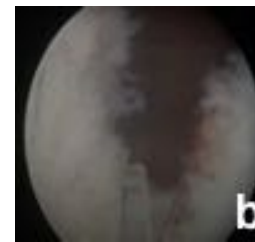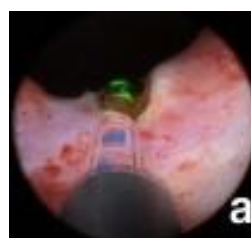


Figure 6. TUIP with Ho:YAG laser pre- (a) and postoperative (b) imaging of the prostate lodge.

c) Transurethral enucleation of the prostate using the Holmium: YAG laser

The Revolix DUO laser, which is also currently used in our institution, has two modes of operation due to the combination of two lasers: one with DPSS (diode pumped solid state) 2.0 micron continuous emission semiconductor - Thulium YAG and the other with holmium YAG - laser using a pulsating wave of 2.1 microns. This method is based on the sequential enucleation of the lobes of benign prostatic hyperplasia or sclerotic tissue, followed by their removal from the bladder.

The operating mode was set with a pulse energy of 2.3 J and a frequency of 8 Hz, the maximum irradiation power was 18.4 W. The light fibre is inserted through the channel of the operating element. HoLEP is performed using a Karl Storz resectoscope (Germany) with a continuous 24-26 F flow (Iglesias), which is the standard resectoscope for TURP. A 30-degree telescope is used during enucleation. Normal saline solution was used for irrigation. The morcellator consists of a handle with tubular blades, an aspiration pump and a pedal. The morcellator is inserted through a 26 F Karl Storz resectoscope. The procedure is performed using the standard three-lobe version or a modified two-lobe version.

The classic or the standard method of three lobes (trilobular) (Figures 7-9).

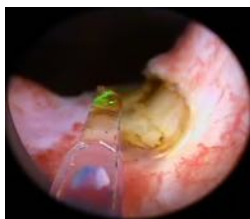

Figure 7. The initial enucleation step. Grooves are made on the right and left of the median lobe of the hyperplastic prostate.

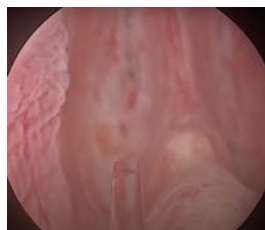

Figure 8. The second step of enucleation. Grooves are fused with the subsequent movement of the enucleated prostatic tissue into the urinary bladder.

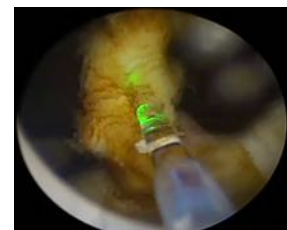


Figure 9. The third step of enucleation. Enucleation of the lateral lobe.

Two-lobe method (bilobular)

The bilobar method consists of incisions made preferably at the 5, 6, or 7 and 12 o'clock positions of a regular quadrant. The incision is deepened into the capsule, as in the classical or standard technique. The median lobe is also enucleated alongside with one of the lateral lobes. The further steps are similar. The advantage of this technique is a decrease in the operating time.

Enucleated tissues are removed from the bladder cavity using a morcellator (Fig. 10). Separate and dense fragments of adenomatous tissue, which are difficult to capture with a morcellator blade, can be removed using a special resectoscope loop (Fig. 11).

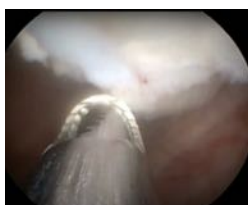

Figure 10. The fourth step of enucleation. Morcellation of the resected tissue.

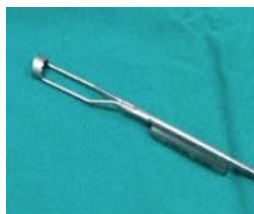

Figure 11. Special resectoscope loop for removing fragments of sclerotic tissue.

2.5. Data statistical analysis

For the purpose of data statistical processing, special files (surveys) were developed, where the anamnesis data, the clinical examination results, the paraclinical and dynamic studies were coded. Excel Microsoft Office and Statistica 7 (Statsoft) were used in processing the

primary data. The indices rates were also calculated.

The values obtained from study groups were compared by using the *Student's t-test* of significance (among the 2 study groups) and *ANOVA* (between several groups) and by identifying the degree of reliability "*p*". *P* values < 0.05 were considered statistically significant. The results are presented as $M \pm m$ (mean \pm standard error). Statistical analysis was performed using the *SPSS Statistics v.24* program (IBM MS Inc.).

3. CLINICAL MANIFESTATIONS AND ENDOSURGICAL TREATMENT OUTCOMES OF INTRA-VESEAL OBSTRUCTION INDUCED BY SCLEROSING CHRONIC NONBACTERIAL PROSTATITIS

Chronic prostatitis alone or in combination with other diseases of the prostate (benign prostatic hyperplasia, etc.) generates many questions for the correct choice of treatment approach. Inflammatory changes in the prostate exacerbate both irritating and obstructive symptoms of prostate diseases, reducing also the quality of life of patients. Frequent flare-ups of chronic prostatitis in the absence of objective indications for surgical treatment (the predominance of irritating symptoms, poor efficacy of adrenergic blockers use) often require the use of additional conservative treatments for this category of patients.

Drug treatment of chronic prostatitis is complex and always long-lasting, which requires a combined use of various groups of drugs that are commonly prescribed for long and repeated treatment courses, depending on its type (bacterial or nonbacterial, inflammatory or non-inflammatory types). It should be noted that a predisposing cause should be determined in order to choose for therapeutic or surgical approach. Unfortunately, there is currently no effective method for the treatment of SDPC/CPPS [3, 19].

In order to confirm SDPC/CPPS and distinguish between inflammatory (III A) and non-inflammatory (III B) variants among this group of patients, which is necessary for proper medication management, 33 patients expected for conservative treatment were assessed for production of NO by phagocytes in the blood, as well as for prostate secretion and ejaculate as a *biochemical marker of inflammatory lesions of the prostate* (SDPC/CPPS).

Following the data analysis on the degree of NO production by phagocytic blood leukocytes and prostate secretion and ejaculate in patients with SDPC/CPPS, an increase in NO production by 109% was found in 25 (76%) patients (main group - 1) % ($p < 0.05$) in blood; an increase in the activity of NO-synthase of macrophages by 75.4% ($p < 0.05$) in the secretion of the prostate gland and by 70.8% ($p < 0.05$) in the ejaculate compared with similar indicators from the control group (healthy people) were also recorded (Table 3).

Table 3. NO generated by iNOS in blood, prostatic secretion and ejaculate of CPPS patients

Study groups No – patients	NO content		
	In blood ($\mu\text{M/L}$)	Prostate secretion ($\mu\text{M/gr.prot}$)	Ejaculate ($\mu\text{M/gr.prot}$)
Main study group -1 (n = 25 de patients)	$57,02 \pm 1,07^{**}$	$7,63 \pm 0,24^{**}$	$7,45 \pm 0,21^{**}$
Main study group -2 (n = 8 patients)	$16,1 \pm 0,83^*$	$3,8 \pm 0,12$	$3,7 \pm 0,20$
Control group (n = 10, healthy men)	$27,23 \pm 3,66$	$4,35 \pm 0,81$	$4,36 \pm 0,41$

Note: * - significance of values compared with the control group ($p < 0.05$); ** - reliability of differences in the studied parameters in patients of the main group 1 (n = 25) and the group 2 (n=8 patients) ($p < 0.05$).

In 8 (24.2%) SDPC/CPPS patients, there was a decrease by 40.8% in nitric oxide amount generated by iNOS in blood ($p < 0.05$), whereas the iNOS activity did not differ significantly in the prostatic secretion and in the ejaculate indices from control group (in healthy men) (Table 3).

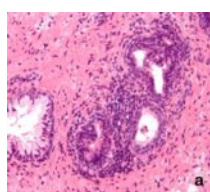
Thus, the 3.5-fold ($p < 0.05$) increase in NO production by macrophage NOS in blood and 2-fold in prostatic secretion and ejaculate in patients of the main group (n = 25 patients) compared to those 8 patients characterizes the inflammatory process in the prostate gland among most patients with SDPC/CPPS, III A, and a non-inflammatory variant of SDPC/CPPS III B in 8 patients.

The study results showed that an increased NO production generated by leukocytes in blood, prostate secretion and ejaculate is a biochemical marker of inflammatory prostate disease in SDPC/CPPS III A.

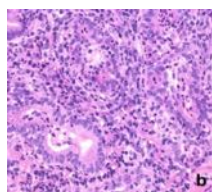
While assessing the patients' clinical condition, the intensity of pain in patients with SDPC/CPPS III A that is the inflammatory type of CNBP (n = 25) according to the NIH-CPSI rating scale was 10.24 ± 1.18 points, urination disorders - 8.84 ± 1.25 points; life quality index - 11.22 ± 0.71 points. For patients with the non-inflammatory CPPS III B of CNBP (n = 8), these indices were as following: 10.83 ± 1.2 ; 9.5 ± 1.2 and 10.8 ± 0.89 , respectively. According to the IPSS international scale, the index of urinary symptoms in CPPS III A (in 25 patients) was 13.36 ± 3.61 , and 14.7 ± 3.0 points in III B (in 8 patients).

The histological assessment via the Masson method (Fig. 12) of tissue removed after resection with a Ho:YAG laser revealed signs of chronic inflammation, which were expressed as:

- diffuse lymphocytic and histiocytic infiltration, predominantly of a perivascular nature, with varying extents of transitions into fibroblastic cells, as well as focal fibrosis;
- formation of follicle-type lymphoid agglomerations, mainly concentrated around the destroyed cystic cavities, with the secretion diffused into the stroma.



a - lymphocytic infiltration (x10; HE)



b - the formation of lymphocyte clusters (x20; HE)

Figure 12. Prostatic tissue in CNBP

According to the histological findings, it was found that patients presented a glandular fibrous prostatic hyperplasia and chronic inflammation in the prostate gland of a varying degree of severity, viz. from minor to maximum severity.

To determine the possibility of a conservative treatment of CNBP or in order to prevent or cease both its development

and subsequent severe consequences (sclerosis, calculi, cysts, etc.), as well as to reduce or improve the incidence of intra- and postoperative complications in case of a subsequent endourological surgical treatment, a comparative study was initiated on the effectiveness of a new anti-inflammatory, antioxidant and anti-fibrotic (anti-proliferative) entomological drug Adenoprosin in 33 patients with SDPC/CPPS with or without IVO-induced urination disorders. The patients aged between 27 to 70 years (mean age- 48.6 years) and with a condition duration of 5 to 14 years were treated within the Clinic of Urology and Surgical Nephrology, at the „Timofei Mosneaga” Republican Clinical Hospital PMHI. The control study group included 10 patients who did not receive adenoprosin. 43 patients with stable SDPC/CPPS III A and B administered "standard" drug treatment with the use of enzyme and vitamin therapy, immunomodulators, and drugs aimed at improving microcirculation. In the group of 33 main patients, in addition to the standard treatment, adenoprosin 250 mg * was prescribed as rectal suppositories, 1 suppository for 30 days.

All parameters were assessed in dynamics after the therapy and then compared with the patients' condition over 1-6 months after the completion of the treatment course with the use of adenoprosin and then compared with the data of the control group (Tables 2; 3; 4; 5 and 6).

The prevalence of the main clinical syndromes in patients from both groups is shown in Table 4.

Table 4. The distribution of patients in groups and the prevalence of the main clinical syndromes of the condition until the initiation of treatment (M \pm m)

Diagnosis	Group, number of patients	Clinical syndromes, % (number of patients)		
		Painful	Dysuria	Erectile dysfunction
Chronic nonbacterial prostatitis	Main (33)	93,9 \pm 8,4 (31)	75,7 \pm 7,5 (25)	78,8 \pm 10,7 (26)
	Control (10)	100,0 \pm 11,4 (10)	100,0 \pm 11,4 (10)	70,0 \pm 14,3 (7)

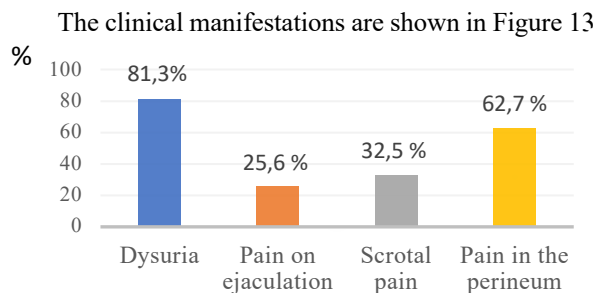


Figure 13. Clinical manifestations in patients included in the study (n = 43).

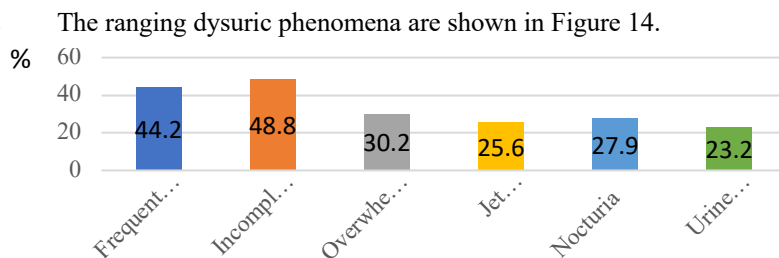


Figure 14. Types of micturition disorders in the cohort (n = 43).

Note: In most cases, patients presented multiple complaints (more than one complaint).

1-3 months after the initiation of entomotherapy, all patients showed a pronounced positive dynamics of the parameters under study: a decrease or lack of LUTS and an improved urination. Pain in the genital area decreased or disappeared in almost all patients.

The dynamics of clinical and laboratory parameters showed that there was a significant improvement in the secretory function of the prostate gland (an increase in the number of lecithin granules) in the main group (Table 5).

Table 5. The dynamics of clinical and laboratory parameters during the follow-up period in patients with CNBP

Indices	The treatment period, group of patients					
	Before treatment		1 month after treatment completion		3 months after treatment completion	
	Main group	Control	Main group	Control	Main group	Control
Leukocytes in the secretion of the prostate per high power field	1,7±0,2	1,9±0,3	1,3±0,2**	1,6±0,3**	1,1±0,2**	1,5±0,3*
Lecithin granules per high power field	1,6±0,5	1,9±0,2	2,3±0,3*	2,2±0,2*	2,3±0,1*	2,2±0,2*
V. mean, (ml/s)	7,1±0,3	7,4±0,5	10,4±0,3***	8,9±0,4***	10,4±0,4***	9,8±0,4*
V. max., (ml/s)	9,36±0,75	9,19±0,53	12,6±0,3***	10,8±0,5***	12,3±0,72***	10,3±0,03***
TRUSP, cm3	39,7±2,94	38,7±1,15	37,1±0,3*	37,0±0,33	36,9±0,17	37,8±0,07*
PSA (ng/mL)	3,7±1,9	3,0±0,7	2,2±0,4	3,0±0,6	3,2±0,6	3,6±0,4

Note: Reliability of values compared with the initial condition: * - $p < 0.05$, ** - $p < 0.01$, *** - $p < 0.001$; between groups of patients examined at the corresponding stage of follow-up: + - $p < 0.05$, ++ - $p < 0.01$, +++ - $p < 0.001$. For convenience of interpretation of changes in the microscopic composition of prostate secretion, the number of lecithin granules was noted on a 4-point scale: 0 - an extremely small amount (unique in c/v); 1 - small (insignificant) number (tens in c/v); 2 is a significant number (up to 100 in c/v); 3 - a large number (also c/v). The number of leukocytes in the secretion of the prostate gland was also assessed on a 4-point scale: 0 (up to 10 i.v.), 1 (10-30 i.v.), 2 (30-50 i.v.), 3 (more than 50 in c/v).

By the end of treatment, there was a sharp increase in the number of leukocytes in the secretion of the prostate gland in patients of the main group, which is an indisputable sign of improved drainage of prostatic alveoli. 1 and 3 months after the treatment completion, the number of leukocytes in the secretion of the prostate gland in the main group was significantly lower compared to the initial parameters from the control group. This indicates a more pronounced anti-inflammatory effect of the proposed treatment. The described changes surely correlated with a decrease in the volume of the prostate during treatment. This fact also confirms the pronounced drainage and anti-inflammatory effect of adenoprosin. It should be noted that a true decrease in the PSA level was not registered either in the main group or in the control group (the mean level of the indicator during the follow-up periods exceeded 3 ng/ml). Probably, in this case, the PSA level was determined not only by inflammatory changes in the prostate, but also by the presence of adenomatous tissue.

The pathological symptoms, characterized by the frequency and severity indices of the syndromes showed a more decreasing tendency and were more pronounced and long-lasting in the main group (Tables 6 and 7).

Table 6. The frequency index of the pathological syndromes during the follow-up period in patients with CNBP

Syndromes	The treatment period, group of patients							
	Before treatment		At treatment completion		1 month after treatment completion		3 months after treatment completion	
	main	control	main	control	main	control	main	control
Painful	3,2±0,3	3,0±0,2	0,9±0,3 ^{***++}	1,6±0,2 ^{**}	1,2±0,3 ^{***++}	1,3±0,3 ^{***}	1,2±0,4 ^{***+}	1,7±0,3 ^{***}
Dysuria	3,1±0,4	2,9±0,2	1,7±0,2 ^{***+}	2,0±0,3 ^{***}	1,6±0,1 ^{***}	2,0±0,3 ^{***}	1,6±0,1 ^{***}	2,1±0,1 ^{**}
Erectile dysfunction	2,8±0,2	2,9±0,1	0,7±0,2 ^{***++}	1,4±0,3 ^{***}	1,1±0,2 ^{***+}	1,7±0,2 ^{***}	0,8±0,2 ^{***++}	1,6±0,2 ^{***}

Note: Value reliability of *s* compared with the initial condition: * - $p < 0.05$, ** - $p < 0.01$, *** $p < 0.001$; between study groups at appropriate stages under study. + - $p < 0.05$, ++ - $p < 0.01$, +++ - $p < 0.001$.

Table 7. Index of manifestations of pathological syndromes during the follow-up period in patients with CNBP

Syndromes	The treatment period, group of patients							
	Before treatment		At treatment completion		1 month after treatment completion		3 months after treatment completion	
	main	control	main	control	main	control	main	control
Painful	6,4±0,2	6,1±0,4	2,3±0,4 ^{***++}	3,7±0,5 ^{***}	2,5±0,6 ^{***++}	3,9±0,4 ^{***}	2,6±0,5 ^{***+}	3,7±0,4 ^{***}
Dysuria	6,2±0,2	5,7±0,4	2,7±0,3 ^{***+}	3,7±0,5 ^{***}	2,7±0,8 ^{***}	3,6±0,4 ^{***}	2,7±0,3 ^{***+}	3,4±0,1 ^{**}
Erectile dysfunction	4,4±0,6	4,4±0,3	2,1±0,2 ^{***+}	3,0±0,5 ^{***}	2,2±0,3 ^{***+}	3,0±0,4 ^{***}	2,6±0,2 ^{***+}	3,1±0,5 ^{***}

Note: Value reliability of compared with the initial condition: * - $p < 0.05$, ** - $p < 0.01$, *** $p < 0.001$; between study groups at appropriate stages under study. + - $p < 0.05$, ++ - $p < 0.01$, +++ - $p < 0.001$.

This group of patients showed a 1.5-2 times lower severity of pain syndrome than in the control group after completion of the treatment course. This ratio was maintained throughout the subsequent follow-up period. Similar results were recorded when assessing dysuria syndrome and copulative dysfunction compared with the control group (Tables 6, 7).

The dynamics of changes in patients' symptoms (IPSS and QoL), as well as the objective indices (Q_{\max} , residual urine and prostate volume) are presented in Table 8 and 9.

Table 8. Dynamics of some clinical indicators in CP patients who administered adenoprosin (n = 33)

Index (mean value)	Before treatment	After treatment	
		3 months	6 months
Number of night-time urination	7,5±2,2	4,2±1,8	2,74±0,34
Residual urine volume of, ml	60,45±6,89	48,48±0,77	35,90±1,17
Volume of residual urine, ml (Q_{\max}), ml/s.	9,36±0,75	12,34±0,12	15,85±0,23
IPSS scoring	18,13±1,11	5,8±1,28	7,1±2,52
Quality of life index (QoL), points	4,33±0,36	2,75±0,16	1,81±0,14
Voiding volume (ml)	180,5±32,3	215,0±28,4	235,0±26,4

Table 9. Dynamics of the IPSS in patients with CNBP

Parameter	Main group (n = 33)		Control group (n = 10)	
	Before treatment	After treatment (3 months)	Before treatment	After treatment (3 months)
IPSS scoring	18,13±1,11	5,8±1,28	17,21±1,3	12,21±0,9

The assessment of the treatment outcomes showed that there was a significant improvement in prostate secretion, uroflowmetry data, PSA levels, and subjective status (IPSS), which was 17-18 points before treatment, and 5.8±1.28 after the treatment in the main group of patients with CNBP/CPPS III, compared with the control group - 12.21±0.9 (Tables 8 and 9). It should be noted that in the main group of patients, irritating symptoms generally decreased according to the IPSS symptom scale. Thus, the complex therapy of adenoprosin, which shows antioxidant and anti-inflammatory effects, should be administered in patients with various forms of CNBP (inflammatory and non-inflammatory type), in combination with modern methods of

physiotherapy, that might significantly increase the treatment efficacy, improve the quality of life and optimize the treatment length, thus, reducing the course of treatment from 3 months to 30 days. Adenoprosin 250 mg, suppositories, contribute to a rapid and significant improvement of general symptoms (in 81% of patients) and urodynamic parameters in the first 3-4 weeks. The drug is effective in chronic prostatitis, both in monotherapy and in complex treatment.

However, despite the favourable treatment results of the patients in this group, it is necessary to mention that 6 (18%) patients with CP, who received treatment with adenoprosin, developed signs of infravesical obstruction (Qmax, residual urine volume, nocturnal urination) over 1-1.5 years. Therefore, in most cases, it is due to the development of another pathology in the patient which leads to subsequent urination disorders (sclerotic changes of the prostate or prostatic stones), thus, requiring a new treatment approach.

10 patients (100%) from the control group showed a decrease in the pain syndrome during the first month after treatment without adenoprosin (Table 6). 6 months after the treatment, the pain sensations remained in 2 patients (20%).

Thus, according to the study results, among all examined patients with CNBP who had no signs of urination disorders, only 27 (82%) patients were not diagnosed with another disease related to the above disorders. The other 6 patients (18%) were diagnosed with another pathology (prostatic sclerosis or calculi) after a thorough examination and diagnostic confirmation, leading to the occurrence of urination disorders.

3.1. Comparative analysis of the transurethral endoscopic treatment outcomes for infravesical obstruction in sclerosing chronic nonbacterial prostatitis

Sclerosis of the prostate (SP) is one of the final stages of the inflammatory process of the prostate gland (chronic prostatitis). This stage is typically characterized by a decrease in the inflammatory activity and, at the same time, the organ is largely replaced by scarring connective tissue. Thus, SP is a consequence of both variants (inflammatory and non-inflammatory factors) of CNBP (category III A and B). In addition, SP is an advanced complication in patients who underwent adenomectomy or TUR for BPH with or without CP. IVO might develop in a number of patients with SP [2, 35].

The treatment of SP is an extremely important issue of modern urology due to the increasing prevalence of this condition, especially in elderly and senile men. Currently, TURP is considered to be the most effective treatment for the removal of IVO, including those caused by sclerosing chronic nonbacterial prostatitis. The treatment of SP is aimed at reducing the intraoperative, early and late postoperative complications, as well as the mortality rate. To achieve this goal, it is necessary to reduce the number of open interventions and increase the use of endoscopic treatment techniques. Although these show positive results and high efficiency, there are related complications and risks. Mortality, although lower in relation to open interventions, remains quite high, particularly in the elderly and senile patients [12]. However, in younger patients who are interested in maintaining antegrade ejaculation, as well as in patients with increased operative risk, TUIP is a feasible option. GEGLYUK O.N. and et al. [9] noted that if this method is justified in elderly patients with BPH-associated calculi, then it is unlikely to be considered an optimal approach in young men, since the risk of complications exceeds the potential benefit in this category of patients.

The study was based on patients' follow-up and complex clinical and laboratory studies conducted in 66 patients aged from 31 to 70 years (mean age 56.6 years) with SP as a result of prior CNBP. This group included transurethral endoscopic interventions and 6 patients who had corresponding urination disorders with persistent pain and dysuric syndrome, in whom conservative entomotherapy with adenoprosin proved to be ineffective. The results of the preoperative examination of patients are presented in Table 10.

Table 10. Preoperative examination findings of patients (n = 66) with prostate sclerosis (mean values)

The mean values of the preoperative parameters	Age (years)	Prostate volume (cm ³)	IPSS/QoL (points)	Q _{max} (ml/s)	Residual volume (ml)
	56,6	28,3	21,3/4,8	8,3	186,4

In accordance with the purpose and objectives of the study and based on preoperative examination data, the patients were divided according to the type of surgical intervention performed: transurethral resection (TUR) (n = 30) or Ho:YAG laser resection (n = 36) of SP.

In order to assess objectively the impact of some surgical methods of endoscopic transurethral resection on the clinical effectiveness of treatment, as well as to determine the most convenient time and method of choice based on the patient's age, functional condition of the body and organ and presence of concomitant diseases, a comparative analysis of changes in the symptomatic indices as related to the urination disorders and quality of life, mean objective indicators of the maximum urine flow velocity, the residual urine volume and the prostate gland was carried out at 1, 3, 6 and 12 months after the surgical intervention. The significance of the evolution of these parameters among the groups of patients was assessed during these periods of postoperative follow-up (Tables 11, 12) and (Fig. 15, 16, 17 and 18).

Table 11. Mean values of preoperative control parameters at various postoperative intervals in patients undergoing transurethral resection of the prostate sclerosis (TURP) (n = 30) (p < 0.001)

Parameters	Preoperatively	Postoperatively			
		1 month	3 months	6 months	12 months
IPSS, points	20,4 ± 0,8	10,7 ± 0,28	8,5 ± 0,23	5,3 ± 0,22	4,69 ± 0,17
QoL, points	4,7 ± 0,58	3,73 ± 0,08	3,2 ± 0,1	2,26 ± 0,08	1,31 ± 0,42
Prostate Vol cm ³	28,2 ± 0,67	15,65 ± 0,12	15,24 ± 0,12	14,92 ± 0,13	19,61 ± 2,20
Q _{max} , ml/s	7,97 ± 0,55	17,36 ± 0,18	18,33 ± 0,02	20,09 ± 0,16	20,71 ± 1,78
Residual Vol., ml	180,83 ± 14,89	51,0 ± 2,85	42,0 ± 2,85	32,0 ± 2,86	18,92 ± 3,4

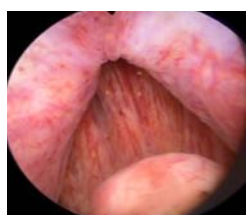

Figure 15. Endoscopic image of prostate sclerosis.

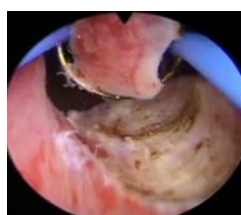

Figure 16. Transurethral electroresection of sclerosing prostate. The resection procedure started at 5 o'clock position of the conventional quadrant.

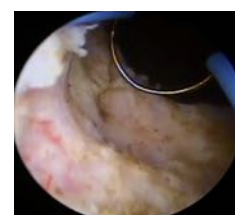


Figure 17. Transurethral electroresection of the sclerosing prostate. The prostate tissue of was excised at 5 o'clock position of the conventional clock where the transverse connective tissue fibres are visualized (resection border, tissue resection is performed at 6 o'clock).

The assessment of surgical outcomes with the subsequent improvement of the urodynamic results demonstrated that TUR in SP is an effective method of treating IVO and contributes to the restoration of micturition, especially in elderly and senile patients, thus, improving their quality of life. Considerably more beneficial results on symptomatic improvement following surgical treatment of prostate sclerosis were predominantly found in patients with obstructive symptoms compared to the irritating ones. According to the research data, beneficial late results were found in 93% of patients with SP-associated CP.

Table 12. Mean values of preoperative and postoperative control parameters in patients undergoing laser TUR for sclerosing prostate (n = 36) (p < 0.001)

Parameters	Preoperatively	Postoperatively			
		1 month	3 months	6 months	12 months
IPSS (points)	22,19 ±2,2	10,1±0,29	8,3±0,32	5,25 ±0,33	4,38 ± 0,37
QoL (points)	4,88 ±0,60	3,58 ±0,09	2,72 ±0,08	1,80 ±0,08	1,23 ± 0,43
Prostate Vol cm3	28,4±0,91	19,7±0,04	19,1±0,20	18,03 ±0,15	18,82 ± 1,61
Q _{max} (ml/s)	8,54 ± 0,77	17,40 ±0,13	20,3±0,18	20,49 ±0,18	21,38 ± 1,49
Residual Vol., ml	191,61 ±11,9	46,6±2,18	43,1±2,12	31,9±1,96	17,05 ± 2,17

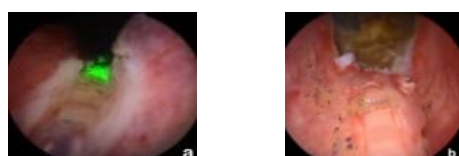


Figure 18. Images of the prostate before (a) and after surgery (b) following enucleation of sclerosing tissue with a holmium laser (HoLEP).

Based on the results obtained (Table 12 and Figure 18), it was concluded that prostate incision with Revolix laser is a fast, safe and perspective procedure for SP, including the recurrent one that might be used in IVO removal accompanied by with satisfactory clinical results.

Moreover, it should be noted that 6 (18.2%) patients with CNBP, who had a prior conservative entomotherapy with the use of adenoprosin showed early evolutionary results of (a higher true percentage of a positive trend, and a significantly lower percentage of postoperative complications - 1 case of urethral fever) and late post-surgical complications: persistent absence of infravesical obstructive symptoms in all 6 patients who had previously administered the entomological drug.

3.2. Characteristics of intra- and postoperative complications and assessment of the effectiveness of transurethral endoscopic treatment of infravesical obstruction in sclerosing chronic nonbacterial prostatitis

Complications that arose in the intra- and postoperative period in patients after TUR and Ho:YAG laser resection of the prostate are presented in Table. 13.

Table 13. Intra- and postoperative complications

Complications	Transurethral resection (n = 30)	Laser resection (n = 36)
Bleeding (with no transfusions)	2(6,7%)	-
Infectious and inflammatory complications	3 (10%)	2 (5,6%)
Acute urethroprostatitis	-	4 (11,1%)
Acute orchiepididymitis	-	2 (5,6 %)
Urinary incontinence	1 (3,3%)	-
Disease recurrence	4 (13,3%)	2 (5,6%)
Urinary retention	2 (6,7%)	3 (8,3%)
Restenosis	-	6 (16,7%)
Urethral fever	-	5 (13,8%)

In emergency postoperative period, the most common complications in both groups were the infectious and inflammatory ones, which occurred in 5 patients (Table 13). The main inflammatory complications (Group 2) were acute urethritis (in 4 patients) and acute orchiepididymitis (in 2 patients). At the same time, the most characteristic complications of the postoperative period of laser resection are urinary retention (8.3%), restenosis (16.7%) and urethral fever (Table 13).

When comparing the effectiveness of transurethral and laser resection of the prostate among both groups of patients, these did not reveal any statistically significant differences. The complication rate assessment showed that transurethral and laser resection are safer interventions compared to others, including open resection of the prostate.

The incidence of hemorrhage in the intra- and postoperative period was found in 6.7% of cases after TUR, which was not observed after laser intervention. This difference can be explained by different mechanisms of hemorrhage arrest in both interventions. During transurethral resection of the prostate gland, coagulation hemostasis spreads evenly over the entire surface of the wound, whereas in laser resection of the prostate, hemostasis is carried locally applied and not on the entire surface of the wound, which contributes to the development of bleeding in the intraoperative period and the immediate postoperative period. Frequency of the relapses assessed showed the greatest differences between the groups. Following a laser resection, recurrence of prostate sclerosis was detected in 5.6% of cases, and after TUR - in 13.3% of cases ($p=0.001$). Only these data alone might confirm the hypothesis that laser resection of the prostate is a more radical intervention compared to TURP.

4. SURGICAL ENDOSCOPIC INTERVENTIONS USED IN DIFFERENTIATED TREATMENT OF CALCULOSIS CHRONIC NONBACTERIAL PROSTATITIS. THE COMPARATIVE ANALYSIS OF THE OBTAINED RESULTS AND TREATMENT COMPLICATIONS OF PROSTATITIS.

The treatments of choice in calculous chronic prostatitis are drug therapy, minimally invasive and open surgical interventions, the number of which is decreasing worldwide. This phenomenon is associated primarily with the emergence of new treatment technologies. A major issue worth considering is the time, namely the condition when the prostate stones should be treated, since most authors recommend that unless complications caused by prostatic calculi are present, a periodic patient's follow up is sufficient [13, 20, 23]. However, it has been stated that the interventions performed to eliminate the calculi do not guarantee their total removal, as well as do not exclude the possibility of stone formation in the future [27].

According to the literature, patients with calculi on the underlying chronic prostatitis require a conservative anti-inflammatory treatment or its combination with various minimally invasive transurethral methods. The transurethral procedure is the method of choice in calculi removal, particularly in patients with difficult-to-treat infections, when the prostatic calculi may perforate the prostatic urethra or protrude beyond its lumen, causing urinary retention, or when these are associated with prostate adenoma, which may lead to an prostatic abscess or IVO, as well as to an impaired sexual functioning in young patients.

Minimally invasive transurethral treatments that improve the symptoms include transurethral resection (TUR), the gold standard in the treatment of BPH, laser resection, and others.

In order to determine the possibilities of transurethral endoscopic treatment in patients with calculous chronic nonbacterial prostatitis, a comparative assessment of the effectiveness of various endoscopic interventions, such as ITUP, TURP and Ho:YAG laser, was performed in 40 patients aged 31-70 years (mean age 59.7 years) with prostatitis, sometimes associated with BNS or BPH of various sizes (more than 3 mm) and shapes, with single or multi-organ localization, complicated by IVO (Fig. 19 a, b, c, d, e, f). These patients presented to the Urology and Endourology clinic with urinary symptoms or pelvic pain for at least 3 months during a 6-month duration prior to hospitalization. Patients were fully assessed to determine the presence of calculous chronic nonbacterial prostatitis and a possible association between prostatic calculi and lower urinary tract symptoms (LUTS) and factors contributing to calculi formation (BPH, SP).

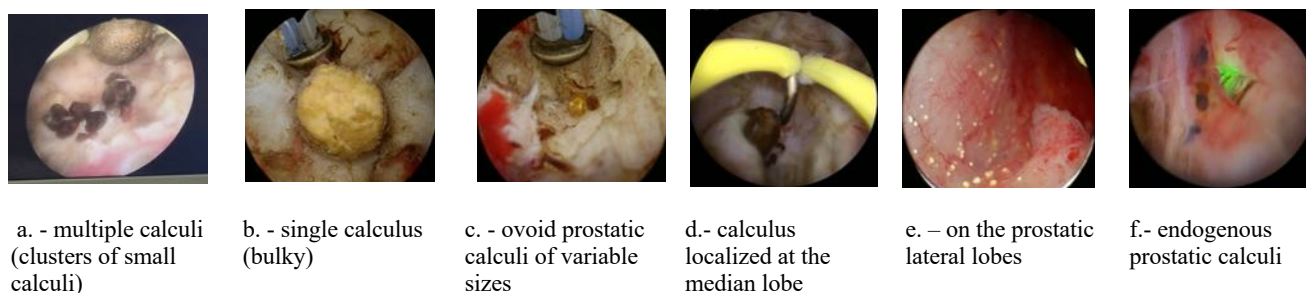


Figure 19. a, b, c, d, e, f. **Prostatic lithiasis (prostatic calculi).**

According to the transrectal ultrasound findings, all patients were divided into two groups. Group 1 – CNBP with prostatic calculi (n-10) treated with ITUP and TURP and group 2 (n-30) - CNBP with prostatic calculi treated with Ho:YAG laser. All patients who underwent transurethral treatment were followed up for at least 12 months (at 1, 3, 6 and 12 month- interval apart).

Therefore, to elucidate the possibilities of endoscopic electrosurgical treatment (group 1), which showed clinical features earlier and at certain postoperative follow-up periods (Table 14), as well as to achieve the maximum effect of transurethral interventions, these underwent some modifications depending on the anatomical and structural condition of both the prostate and its adjacent tissues, being determined as a causative factor of the symptoms persistence and condition resistance among patients.

Table 14. **Clinical variables in males with prostatic calculi who underwent various methods of endoscopic transurethral resection of the prostate ($M \pm m$; $p < 0,05$)**

Parameters	Before treatment	TUR incision or resection, n = 10 patients			
		1 month	3 months	6 months	12 months
Prostate vol. (cm ³)	56,74 \pm 21,5	33,94 \pm 4,87	32,05 \pm 5,15	30,64 \pm 5,23	29,31 \pm 5,3
Total IPSS (points)	22,9 \pm 2,42	15,6 \pm 0,62	10,7 \pm 0,5	8,7 \pm 0,78	8,8 \pm 0,7
Q _{max} (ml/s)	9,34 \pm 1,29	13,65 \pm 0,41	15,82 \pm 0,44	18,29 \pm 0,42	19,56 \pm 0,46
QoL (points)	5,0 \pm 0,66	3,0 \pm 0,3	2,1 \pm 0,31	1,7 \pm 0,26	1,2 \pm 0,24
Residual vol. (ml)	92,9 \pm 17,95	48,4 \pm 5,56	38,9 \pm 5,97	30,8 \pm 6,79	19,4 \pm 9,38

The main transurethral endoscopic methods used in patients were transurethral incision of the prostate (ITUP), transurethral resection of the prostate (TURP), subtotal organ resection, and a combination of these methods. TU Incision and resection of the prostate was performed in 10 patients, aiming at arresting the retention processes within the organ on the underlying pathological evolution with minimal removal of prostate tissue. Thus, the TU incision or resection excluded the causative factor of secretion retention and, as a result of ducts opening, their stagnant contents were evacuated (Figure 20-22. Schemes).

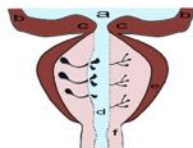

Figure 20. Scheme. Removal of stagnation in transurethral resection of the prostate. Sagittal incision of the prostate

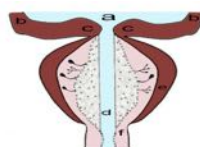


Figure 21. Scheme. Pathological paraurethral process and obstruction of prostate ducts. Sagittal incision of the prostate.

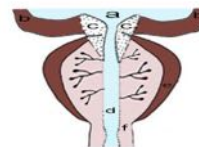
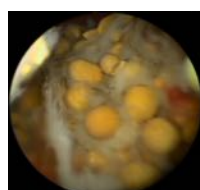


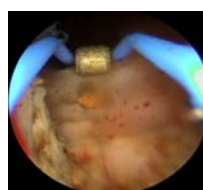Figure 22. Scheme. Circular transurethral resection of the prostate and bladder neck.

Note: Figures 20-22: a - urinary bladder; b - detrusor; c - internal sphincter; d - seminal colliculus; e - prostate gland tissue; f - the external sphincter.

When multiple calculi or foci of sclerosis were detected in the prostate, a subtotal resection was performed to remove the entire tissue of the organ and calculi (Fig. 23).



a



b

Figure 23. Transurethral resection with removal of prostatic calculi. Pre- (a) and postoperative (b) images of the prostate after TUR.

During resection, the calculi were separated and removed from all 10 patients with different conditions of calculi-related lithiasis (calculous prostatitis) (Figure 24; 25; 26).

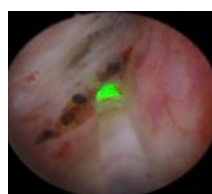


Figure 24. **Bulky prostatic lithiasis accidentally discovered** (a – intraoperative features; b – complete stone removal mass).

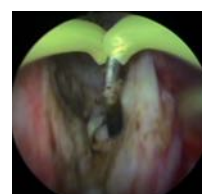
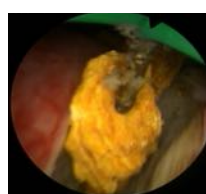
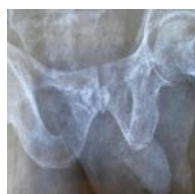

Figure 25. **Residual prostatic cavity after bulky prostatic stone removal** (a – urethrocytographic aspects; b, c – endoscopic aspects).

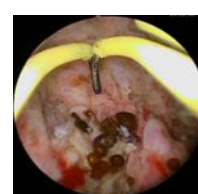

Figure 26. **Prostatic calculi revealed during interventions for prostate adenoma.**

In all cases, surgery lasted from 40 to 105 minutes, the mean time being 92.5 minutes. The mass of the removed tissue was different depending on the underlying pathology. The bladder was drained via a urethral catheter during 2-3 days. The resected tissues were examined histologically. In all patients, the early postoperative period showed no complications and there was no bleeding in almost all cases. At the first control examination, a significant improvement in subjective symptoms and an increase in the maximum urine flow velocity, as well as a decrease in residual urine were also revealed (Table 14).

Therefore, transurethral resection of calculous chronic nonbacterial prostatitis shows a high clinical efficacy due to rapid restoration of micturition quality. The significant indices of effectiveness and safety allow considering these methods of treatment as effective in treatment of calculous CNBP. The main advantage of ITUP over TURP, especially in younger patients, which also should be considered in the elderly, is the lower rate of retrograde ejaculation.

30 patients aged 51-70 (mean age 60.5 years) with LUT symptoms due to prostatolithiasis (calculous CNBP) underwent the surgical intervention of enucleation and resection with Ho:YAG laser. The Ho:YAG laser procedure (up to 20 W) lasted on average 69 minutes. The laser was applied to 4 areas (at 2, 4, 8, 10 o'clock position of the conventional quarant) depending on the site, size and volume (number - single or multiple) of the calculi (Figure 27).

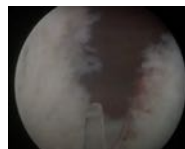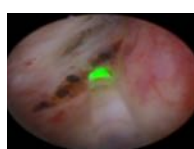


Figure 27. **Pre- (a) and postoperative (b) images of the prostate after the enucleation of prostate tissue and calculi with HoLEP laser.**

The mean surgery length was 69 minutes, laser enucleation lasted 48 minutes, and morcellation was 18.3 minutes. The mean volume of enucleated adenomatous tissue was 36-87 gr. The maximum urine flow rate, the residual urine volume, PSA, and the prostate volume were

determined in patients before and after the intervention. Patients were examined postoperatively at 1, 3, 6 and 12 months. Complete data on the micturition are presented in table 15.

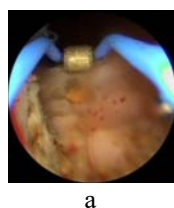
Table 15. **Preoperative and follow-up examination results of the patients (n = 30) with prostatic lithalsas, undergoing HoLEP laser enucleation (mean parameters; p < 0,05)**

Parameters	Before surgery	1 month	3 months	6 months	12 months (n = 28)
Prostate vol. (cm ³)	42,5 ± 14,19	28,43 ± 1,8	27,3 ± 1,94	25,8 ± 2,02	25,21 ± 2,3
Qmax (ml/s)	9,08 ± 1,8	12,08 ± 0,2	14,07 ± 0,24	19,11 ± 0,31	19,93 ± 0,06
IPSS (points)	23,2 ± 2,57	16,43 ± 0,4	12,6 ± 0,4	9,5 ± 0,46	8,57 ± 0,48
QoL (points)	4,83 ± 0,51	2,9 ± 0,1	2,23 ± 0,1	1,7 ± 0,13	1,5 ± 0,14
Residual vol. (ml)	94,8 ± 47,4	40,4 ± 7,87	34,23 ± 8,51	25,83 ± 8,74	15,25 ± 9,6

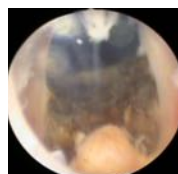
The complication rate after Holmium enucleation was generally low. The following intraoperative complications were recorded: perforation of the prostate capsule - 1 (5.0%) case,

damage to the bladder neck walls during morcellation - 1 (5.0%) case, hemorrhage - 1 (5.0%) case, ureteral tract damage - 1 (5.0%) case, incomplete bladder perforation in the triangle area - 2 (6.6%) patients. Repeated transurethral interventions were required to remove the prostate tissue in 1 (5.0%) patient. The following postoperative complications were revealed: transient urinary incontinence (after 2 weeks) - in 2 (10.0%) patients, stress urinary incontinence - in 1 (5.0%) patient, damage to the bladder mucosa occurred in 1 case, especially in bulky prostate, also, one patient underwent bladder neck resection due to its sclerosis. Orchiepididymitis was confirmed in one case among postoperative complications. Urethral stricture made up 1.6% and bladder neck sclerosis - 3.3%. Following the dynamics of six-month follow-up, 9 patients showed an improving tendency of these indices. One patient (5%) was diagnosed with residual tissue in the prostate lodge typically at the apex, and therefore TURP was performed. Urinary incontinence usually resolved spontaneously within 3 weeks. Two patients complained of urinary tract irritation symptoms, commonly self-limiting ones, also after 3 weeks. Irritating symptoms were present in 28% of patients within 1 month and in 10% of patients within 3 months after surgery. However, the symptoms commonly resolved spontaneously and were treated with non-steroidal anti-inflammatory drugs. According to the literature, these complications are a typical of HoLEP and patients should be properly informed in order to achieve good postoperative cooperation. It should be noted that positive results of high efficiency and safety of laser enucleation and vaporization (ablation) methods were found in the management of calculous CNBP of various sizes, IVO and LUTS, being also described KUNTZ R.M. et.al (2002); GILLING P.J. et.al. [142] (2008); GHICAVII V. et al. [5, 6, 10], when using laser energy for vapoenucleation.

Therefore, standard monopolar endoscopic resection and laser vaporization can be recommended as first-line treatment for surgical indication of calculous PCAB (Figure 28) [29].

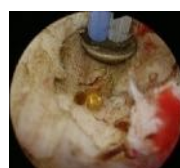

a

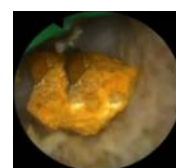


b

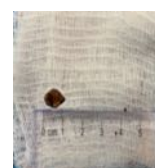
Figure 28. Endoscopic image of the prostate after TURP (a) and laser (b) intervention.



a



b



c

Figure 29. Prostatic calculi: a – typical (ordinary) calculi; b, c – calculi sized 12mm.

Following the surgical interventions performed on 40 patients, 84 calculi were extracted, the sizes ranging from 1 to 5 mm. Only 2 calculi exceeded these dimensions and were 12 mm. (Figure 29).

Thus, the clinical efficacy of holmium laser enucleation and monopolar transurethral resection of the prostate (TURP) is comparable. However, unlike TURP, holmium laser enucleation is not limited to the volume of the prostate and can be carried out in various gland sizes. This method provides a lower risk of intra- and postoperative bleeding, eliminates the development of the "water intoxication" syndrome, helps to reduce the possibility of developing infectious and inflammatory complications by decreasing the urethral catheter time and in-patient stay.

Furthermore, holmium laser enucleation of the prostate is believed to be an effective and safe surgical method in the treatment of IVO caused by CNBP and its consequences, which is manifested by a rapid micturition recovery, being available to all categories of patients. Based on the results obtained, it may be concluded that the use of laser enucleation is possible in patients with various sizes prostates, provided that there are technical possibilities for using a morcellator. Laser interventions can also be performed in patients in whom electrosurgery is contraindicated (carriers of pacemakers) and in coagulopathy [6], in patients with chronic renal failure and those who require chronic dialysis in obstructive type of CNBP.

Absolute contraindications for Holmium transurethral enucleation include the patient's severe condition, decompensation of vital organs, acute inflammatory conditions, which are no exception to those characteristic of any other planned surgical intervention. The intervention cannot be performed if it is technically impossible to insert a resectoscope through the urethra into the bladder (ankylosis of the hip joints, severe and extended urethral stricture). A relative contraindication is the presence of a microcyst, which can interfere with the safety of morcellation of hyperplastic tissue.

Therefore, based on the study results, and in order to determine the need and possibility of endoscopic transurethral interventions in calculous CNBP, it was concluded that an endoscopic procedure is a first-line treatment and may be used in calculi removal (Figure 28 and 29). Despite the literature reports stating that in the absence of complications caused by prostate calculi, periodic patient's follow-up is sufficient, or that patients with independent, uncomplicated prostate calculi do not require special treatment, as well as that these procedures do not guarantee the removal of all stones, nor excluding the possibility of future calculi formation in the future, differentiated methods (TUR or laser) can and should be used for the following conditions:

- infections that are difficult to treat (calculi may hinder the appropriate drug penetration and stone films represent a source of infections);
- calculi associated with prostate adenoma;
- protrusion, penetration or perforation of the prostatic urethra by calculi causing urinary retention or IVO;
- leading to prostatic abscess;
- CNBP-induced IVO and its consequences (prostatolithiasis);
- multiple or bulky prostatolithiasis;
- inefficient long-term conservative treatment, etc.;
- malignancy;
- IVO due to CP exacerbation, as well as ineffective conservative treatment, especially when the inflammation is combined with prostate calculi.

5. SYNTHESIS OF THE OBTAINED RESULTS

The study was aimed to develop a scientific basis for determining the differential therapy of CNBP and its consequences, viz. post-inflammatory sclerosis of the prostate and chronic calculous prostatitis causing IVO. Transurethral endoscopic surgical treatment was prescribed to the group under study with CNBP-induced IVO and its consequences - prostate sclerosis of various sizes and conditions (zonal or massive scarring of the prostate) and prostatolithiasis of various localizations, sizes and volumes (single, multiple, external, internal, etc.), of various post-inflammatory and postoperative etiology, investigated either by intravenous urography or by computed tomography, in order to reduce the risk of complications and allow the use of appropriate interventions.

A prospective etiopathological study including clinical and paraclinical assessment upon that moment and in dynamics, of organs and systems contributed to the development of a consistent concept of differentiated treatment. The study used significant personal and factual material for an in-depth research analysis, which contributed to the development of a consistent diagnostic algorithm and differential transurethral endoscopic treatment for the study of chronic nonbacterial prostatitis, its modalities and consequences resulting in IVO.

The introduction of diagnostic assessment and modern sequential treatment will increase their effectiveness, efficiency and cost-effectiveness. Figure 30 summarizes the most necessary and relevant diagnostic approaches and conceptualized processes, transurethral endoscopic methods of differential treatment of CNBP and its consequences - sclerosing and calculous prostatitis leading to IVO. The study also describes the step-by-step and detailed manner of

diagnosing and treatment of a patient with this acquired pathology, from the moment of the initial consultation, repeated visits, including the preoperative period, as well as the recommended long-term postoperative patient's follow-up.

Transurethral endoscopic treatment includes various methods, such as TU incision and resection, laser incision and resection, used in treatment of IVO, including those caused by the CNBP consequences, thus, minimizing the risk of complications due to minimum invasiveness and providing greater safety for the patient. The method of choice for IVO caused by the consequences of untreated CNBP increases the predictability of a successful intervention and minimizes the risk of complications. Contraindications to the implementation of transurethral endoscopic methods are the acute inflammatory conditions, decompensation of vital organs and acute inflammatory conditions, which are no exception as in any other planned surgical intervention. Interventions are not performed if it is technically impossible to insert a resectoscope through the urethra into the bladder (ankylosis of the cytofemoral joints, severe and extensive urethral stricture).

Thus, endoscopic treatment methods used in CNBP-induced IVO and its subsequent complications may be an alternative to previously known and routine interventions. They show identical or even greater clinical outcomes, as well as a higher cost-effectiveness compared to traditional surgical methods. Due to their high efficiency and minimal trauma rate, transurethral endoscopic interventions have become the methods of choice in the treatment of a number of urological diseases. Since CNBP and its consequences, such as prostate sclerosis and prostatolithiasis, rank the first places among urological diseases with an incidence of about 90-95% showing a significant number of referrals to urologists, transurethral endoscopic treatment is considered a priority.

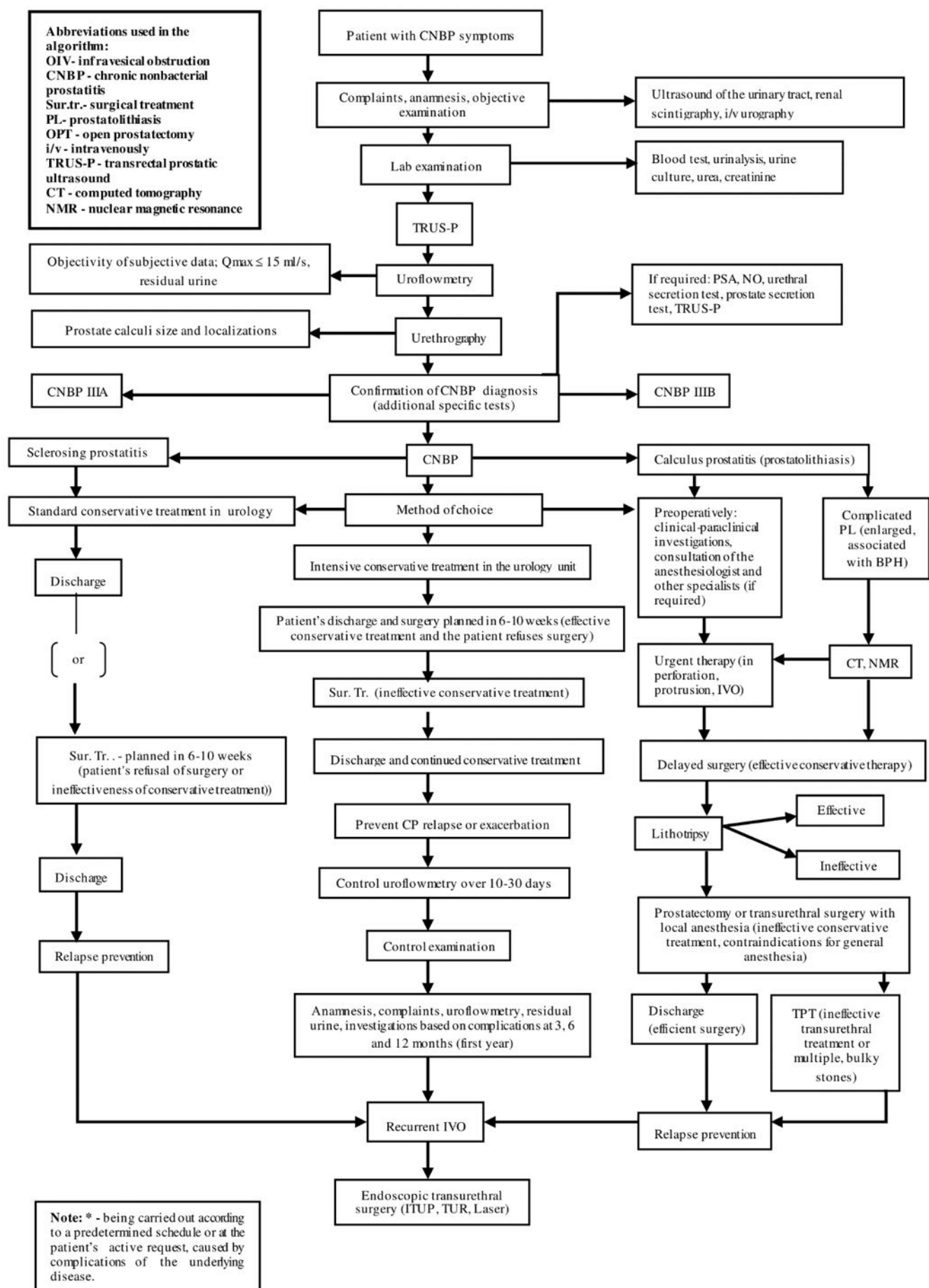


Figure 30. Algorithm for the diagnosis and sequential treatment of IVO caused by CNBP and its consequences (sclerosing and calculous prostatitis)

GENERAL CONCLUSIONS

1. Transurethral endoscopic interventions (TUR and Ho:YAG laser) can effectively treat patients with IVO caused by prostate sclerosis and prostatolithiasis, resulting from CNBP. The high clinical efficacy of holmium laser enucleation and monopolar transurethral resection of the prostate might be compared, preferably due to a shorter intervention, recovery and hospital stay length, less trauma, and lower frequency of both life-threatening complications and relapses. These interventions are the methods of choice and are more preferred to other surgical approaches used in the treatment of these pathologies. Transurethral resections (TUR and laser) of the prostate lasts for 60-90 minutes, thus, exceeding these time intervals, might increase the risk of development of intra- and postoperative complications.
2. TUR of the prostate is associated with less trauma, lower complication rate and significantly reduced mortality, thus showing the same effectiveness compared to previously used approaches. It is an effective method of primary surgical treatment of infravesical obstruction of a varying severity degree caused by CNBP and its complications (sclerosis of the prostate and prostatolithiasis), which contributes to the restoration of urination especially in elderly and senile patients and improving their quality of life.
3. Transurethral surgery using a holmium laser is an effective and safe method of treating patients with CNBP of various sizes, volumes and localizations and its related consequences. It is not limited by the volume of sclerotic or calculous prostate, it might be used in management of various sizes of the prostate, being characterized by rapid recovery of the quality of urination; it also provides a lower risk of intra- and postoperative hemorrhagic complications and of urinary incontinence; it prevents the development of the "water intoxication" syndrome, helps reducing infectious and inflammatory complications by reducing the length of urethral catheterization and patient's hospital stay. This intervention exhibits good tolerability, low trauma and the possibility of a safe duration without changing the main body balances, and also can be an alternative to the standard TURP when choosing a surgical method for all categories of patients with CNBP and its consequences (sclerosing and calculous). The method is lower to radical transurethral electroresection of the prostate and is accompanied by a longer recovery period (due to maintenance of postoperative irritating symptoms).
4. The priority of Ho:YAG-laser transurethral resection of the prostate in treatment of patients with CNBP associated with IVO refers to the possibility to perform surgery alongside with some other underlying conditions (comorbidities and concomitant diseases), including those in whom electrosurgery is not indicated (due to pacemakers) and those undergoing coagulopathy (treated with anticoagulants), patients with chronic renal failure and those who need constant dialysis. Transurethral intervention with Ho:YAG laser in prostate sclerosis due to CNBP proceeds more easily if prior adenoprosin treatment was administered, followed by a favourable course in the early period and having a much lower incidence of postoperative complications than in laser resection performed for prostate sclerosis in patients with CNBP with no corresponding treatment.
5. Transurethral incision of the prostate (TUIP) is an alternative endoscopic method for the treatment of subvesical obstruction in young patients with calculous CNBP, which allows to remove the obstruction by reducing the constriction secondary to the incision of the prostate (rather than by tissue resection as in the case of TURP). This therapeutic method is appropriate in the same category of patients with chronic prostatitis of moderate severity or in patients with comorbidities, in which exeresis is contraindicated, since it is a simple surgical intervention, lasting relatively shorter than TURP, and where fluid and electrolyte disturbances do not occur. Moreover, it also requires a significantly lower amount of lavage fluid, followed by a reduced complication rate and satisfactory long-term outcomes. Severe

bleeding accompanied by blood transfusion is also extremely rare, followed by a lower incidence (up to 10%) of retrograde ejaculation compared to TURP (approximately 50-95%). High efficiency and low traumatism of endoscopic interventions made it possible to expand the range for their indications, whereas in some cases these are considered the methods of choice in the treatment of a number of urological conditions, such as CNBP with micturition disorders (manifested through IVO) and complications such as prostatic sclerosis, prostatic calculi, etc.

6. To confirm the diagnosis of chronic nonbacterial prostatitis (chronic pelvic pain syndrome), as well as distinguish between the inflammatory CNBP (CPPS III A) or non-inflammatory CNBP (CPPS III B), alongside with data on clinical examination, anamnesis, relevant laboratory and instrumental studies, it is important and necessary to determine the NO production by phagocytic leukocytes from blood, prostate secretion and ejaculate that is a biochemical marker, characterizing the evolution of the inflammatory process in the prostate.
7. Administering the entomological drug adenoprosin to patients with irritating symptoms accompanied with moderate urination disorders in combination with standard complex physiotherapy for chronic nonbacterial prostatitis of III A and III B category (inflammatory and non-inflammatory), might improve the patients' quality of life and optimize the timing of appropriate medication. In turn, it also contributes to reducing the risk of CNBP consequences, as well as of early (infectious-inflammatory), late (cicatricial-sclerotic) and intra- and postoperative complications during transurethral endoscopic treatment, which is carried out in this category of patients.

PRACTICAL RECOMMENDATIONS

1. Transurethral resection (TURP) and Ho:YAG laser resection of the prostate in patients with chronic nonbacterial prostatitis should be performed if long-term drug treatment is ineffective, as well as in cases of intercurrent conditions where adenomectomy is contraindicated.
2. When conducting repeated surgeries after laser interventions, transurethral electroresection of the prostate should be preferred, which results in a pronounced scarring of the tissue following laser interventions.
3. Due to low trauma and possible decrease in the operating time, monopolar transurethral resection and Ho:YAG laser resection are the methods of choice in treatment of patients with prostate sclerosis, who are at high surgical risk.
4. Patients with chronic nonbacterial prostatitis/chronic pelvic pain syndrome III A with severe symptoms of micturition disorders and sclerotic changes in the prostate tissue are recommended to undergo the test for inflammatory biochemical markers, such as NO, oxidative stress, and the kallikrein-kinin system, in order to confirm the diagnosis.
5. The level of intraoperative bleeding in patients with chronic nonbacterial prostatitis during transurethral resection of the prostate depends on the gland size, patient's hypertensive condition and coagulation system disorders.
6. In order to reduce postoperative infectious and inflammatory complications in patients with prostate sclerosis on the underlying chronic prostatitis, the anti-inflammatory and immunocorrective therapy, including adenoprosin should be administered prior to TURP.
7. To reduce intra- and early postoperative complications in patients with CP, Adenoprosin should be given for 1-2 months prior to transurethral resection of the prostate gland, which will facilitate the surgical intervention and reduce the inflammatory and sclerotic phenomena, as well as decrease the processes of lithiasis.

8. The use of Adenoprosin 1-2 months before transurethral resection of the prostate might reduce both the prostate volume and the incidence of intraoperative and postoperative complications.

SELECTIVE BIBLIOGRAPHY

1. Dewitt-Foy M.E., Nickel J.C., Shoskes D.A. Management of chronic prostatitis/chronic pelvic pain syndrome. *European urology focus*. 2019, Volume 5, Issue 1, pages 2-4.
2. Engelhardt P.F., Seklehner S., Brustmann H. et al. Association between asymptomatic inflammatory prostatitis NIH category IV and prostatic calcification in patients with obstructive benign prostatic hyperplasia. *Minerva Urol. Nefrol.* 2016; 68(3):242-9.
3. **Колца А.Т.,** Гикавый В.В. Интра- и послеоперационные осложнения трансуретральной эндоскопической резекции при абактериальном склерозирующем простатите. Тез. Росс. Нац. Конгресса „Человек и лекарство”. Кардиоваскулярная терапия и профилактика, 2021, 20.S1: 99-99.
4. **Colța A.** Possible differential diagnosis of various chronic nonbacterial prostatitis. *Moldovan Medical Journal*. March 2021; 64(1), Nr.2, p.33-36, ISSN 2537-6373.
5. Sharp Victoria J., Elizabeth B., Prostatitis: Diagnosis and Treatment. *s. Am Fam Physician*. 2010 Aug 15; 82(4):397-406.
6. Кузьмин М.Д.и др. Патогенетическое лечение абактериального простатита. *Урол.*, 2020 „№ 5.с. 348.
7. Сейдуманов М.Т. Современные диагностические и лечебные тактики при калькулезном простатите. *Scientific-Practical Journal of Medicine, „Vestnik KazNMU”*, 2017, 3 (2).
8. Мазо Е.Б., Школьников Е.М. Синдром хронической тазовой боли (обзор литературы) // *Consilium medicum*. 2008, № 10. № 4 С. 49-51.
9. Canani S., Mujtaba N., Sadler P. Acute and chronic prostatitis. *InnovAiT*, 2021, 14(1), 33-37.
10. Doiron R.C., Nickel J.C. Chronic Prostatitis/Chronic Pelvic Pain Syndrome. In: *Urologic Principles and Practice*. Springer, Cham, 2020. p. 287-302.
11. Винник Ю.Ю., Кузьменко А.В., Амельченко А.А. Клинико-биоимпедансометрические особенности проявлений хронического небактериального простатита с воспалительным компонентом у молодых мужчин. *Андрология и генитальная хирургия*, 2021, 2022 (1), 38-42.
12. **Colța A.** Manifestările clinice și managementul tratamentului chirurgical al obstrucției infravezicale provocate de consecințele PCAB. *Arta Medica*, 2021, 1 (78) p. 34-45, ISSN:1810-1852.
13. Dumbraveanu I., Ciuhrii C., Tanase A. Anti-inflammatory activity of Adenoprosin in nonbacterial prostatitis. *The Moldovan Medical Journal*, 2017, Vol. 60, No 4. p. 4-10.
14. Евдокимов В.В., Ковалык В.П. и др. Диагностика и лечение абактериального ХП/СХТБ III, ассоциированного с герпесвирусами. *Урология*, 2019, 3: 23-30.
15. Schaeffer A.J., Landis J.R., Knauss J.S. et al. Demographic and clinical characteristics of men with chronic prostatitis: the National Institutes of Health Chronic Prostatitis Cohort Study. *J. Urol.* 168: 593-598, 2002.
16. Krieger J.N., Nyberg L.Jr., Nickel J.C. NIH consensus definition and classification of prostatitis. *JAMA* 1999; 282(3):236-237.
17. Zhang J. et al. Chronic prostatitis/chronic pelvic pain syndrome: A disease or symptom? Current perspectives on diagnosis, treatment, and prognosis. *Amer. Jour.of men's health*. 2020, Volume 14, Issue 1.
18. Franco J.V.A., Tirapegui F.I., Turk T. et al. Pharmacological interventions for treating chronic prostatitis/chronic pelvic pain syndrome (Protocol). *Cochrane Database of Systemic Reviews*. 2017; 2.
19. Rees J., Abrahams M., Doble A., Cooper A. Prostatitis Expert Reference Group (PERG). Diagnosis and treatment of chronic bacterial prostatitis and chronic prostatitis/chronic pelvic pain syndrome: a consensus guideline. *BJU Int*. 2015; 116(4):509-525.
20. Аль-Шукри С.Х., Солихов Д.Н. Современные методы лечения хронического простатита (обзор литературы) – *Нефрология*. 2009.
21. Ghicavii V. Comparative outcome assessment of Holmium:YAG laser and bipolar transurethral resection (bipolar TURP) in the treatment of BPH. In: *International Health*. Issue 6(2) November, volume 9, Oxford University Press, 2017, p. 1341-1351. IF: 1,621.

22. Неймарк А.И., Максимова С.С. Влияние комплексной терапии больных хроническим абактериальным простатитом на гемодинамику предстательной железы. Экспериментальная и клиническая урология, 2019, 3. с. 144-150.
23. Гориловский Л.М., Доброхотов М.М. Трансуретральная резекция в лечении склероза предстательной железы у больных пожилого и старческого возраста. Материалы XI съезда урологов России. М., 2007, с. 436-437.
24. Ghicavii V. Endovideochirurgia în urologia națională: evoluția tehnologică și a criteriilor de apreciere. Revista de Științe ale Sănătății din Moldova. 25(3). 2020, p.144-153.
25. Геглюк О.Н., Мегера В.В., Белов В.Ю. К вопросу о камнях предстательной железы. Актуальні проблеми сучасної медицини: Вісник української медичної стоматологічної академії 2015;15(4):165-168.
26. Shoskes D.A., Katz E. Multimodal therapy for chronic prostatitis/chronic pelvic pain syndrome. Curr. Urol. Rep 2006; 6: 296-299.
27. Сомова Л.М., Плеханова Н.Г. – Оксид азота как медиатор воспаления – Вестник, ДВО РАН, 2006, № 2, с. 77-80.
28. Спиридоненко В.В. Хронический калькулезный простатит: этиология, патогенез, диагностика и современные методы лечения. Здоровье мужчины, 2016, 4 (59): 6-10.
29. **Colța A., Ghicavii V.** Entomoterapia în prostatita cronică abacteriană. Sănătate Publică, Economie și Management în Medicină. 2021, 1(88), p.71-78, E- ISSN 2587-3873.

LIST OF SCIENTIFIC PAPERS PUBLISHED ON THE PH.D.TOPIC

- **Articles submitted to scientific journals abroad:**

- ✓ **articles submitted to journals and other international databases**

1. **Colța A., Ghicavii V.** Method for treating chronic calculous abacterial prostatitis complicated by infravesical obstruction. In: *Buletin Științific Supliment „Cadet INOVA”*. 2022, nr.7/22, p. 190-199. ISSN 2501-3157.
2. **Colța A.** Assessment of the endourological surgical outcomes in patients with nonbacterial inflammatory sclerosis of the prostate. *Surgery. Eastern Europe*, 2022, vol. 11, № 2, 2022, p. 237-242.

- **Articles submitted to approved national scientific journals:**

- ✓ **articles in category B magazines**

3. **Colța A.** Possible differential diagnosis of various chronic nonbacterial prostatites. In: *The Moldovan Medical Journal*. 2021, vol. 64, nr.2, p.33-36. ISSN: 2537-6373.

- ✓ **articles in category B magazines**

4. **Colța A., Ghicavii V.** Entomoterapia în prostatita cronică abacteriană. În: *Sănătate Publică. Economie și Management în Medicină*. Chișinău, 2021, 1(88), p.71-78. E-iSSN 2587-3873.
5. **Colța A.** Manifestările clinice și managementul tratamentului chirurgical al obstrucției înfravezicale provocate de consecințele prostatitei cronice abacteriene. În: *Arta Medica*. 2021, nr.1(78), p.34-45. ISSN: 1810-1852.
6. **Colța A., Ghicavii V.** Rezecția transuretrală în prostatita cronică abacteriană litiazică. În: *Revista de Științe ale Sănătății din Moldova (Moldovan Journal of Health Sciences)*. Chișinău, 2022, nr.1, p. 45-54. ISSN: 2345-1467.
7. **Colța A., Ghicavii V.** Predisposing factors for surgical complications in chronic prostatitis and fibrosis of the prostate. În: *Revista de Științe ale Sănătății din Moldova (Moldovan Journal of Health Sciences)*. Chișinău, 2022, nr. 30(4), p. 27-31. ISSN: 2345-1467.
8. **Colța A., Ghicavii V.** Inflamația cronică și scleroza prostatei. Factori predispozanți ai complicațiilor chirurgicale a prostatitei cronice. În: *Buletinul Academiei de Științe a Moldovei. Științe Medicale*. Chișinău, 2022, nr. 3(74), p. 120-124.
9. **Colța A.** Tratamentul medicamentos în ameliorarea rezultatelor și diminuarea complicațiilor intervențiilor transuretrale endoscopice în prostatita cronică abacteriană sclerozată. În: *Buletinul Academiei de Științe a Moldovei. Științe Medicale*. Chișinău, 2021, nr. 3(71), p. 195-199.

- ✓ **articles in category C magazines**

10. **Colța A., Vladanov I., Pleșacov A., Ghicavii V. și al.** Fibroza prostatei – aspecte contemporane de tratament și profilaxie. În: *Arta Medica*. 2019, nr. 1(70), p.64-67. ISSN 1810-1852.

- **Summary / abstract / thesis presented within scientific conferences:**

- ✓ **international conferences held abroad**

11. **Колца А.Т.** Трансуретральная инцизия простаты с использованием лазера Ho:YAG при инфравезикальной обструкции у больных, перенесших хронический абактериальный простатит. В: сборник трудов VIII Российского Конгресса по Эндоурологии и новым технологиям с международным участием. Москва. 2022, с. 35-36.
12. **Колца А.Т.,** Гикавий В.В. Интра- и послеоперационные осложнения трансуретральной эндоскопической резекции при абактериальном склерозирующем простатите. В: *Тезисы Российского национального Конгресса «Человек и лекарство»* Сборник тезисов. Спец. выпуск *Кардиоваскулярная терапия и профилактика*. Москва, 2021, 20(1S):1-118, с. 99.
13. Гикавий В.В., **Колца А.Т.** Лазерная трансуретральная резекция (Ho:YAG) при хроническом абактериальном простатите, осложненном склерозом простаты. В: *Сборник тезисов XXI Конгресса Российского общества урологов. Урология*. Санкт-Петербург, 2021, № 5, с. 51-52.

- ✓ **international conferences held in the Republic of Moldova**

14. **Colța A.,** Ghicavii V. Endoscopic treatment with Ho:YAG laser at the patients with chronic lithiasis nonbacterial prostatitis. In: *MedEsperaInternational Medical Congress for Students and Young Doctors*. Chisinau, 2022, p. 409. ISBN 978-9975-3544-2-2.
15. **Colța A.,** Vasiliev V., Pleșacov A., Vladanov I. Laser Ho:YAG versus transurethral incision of prostate (ITUP) in treatment of prostate sclerosis areas after chronic prostatitis. In: *MedEsperaInternational Medical Congress for Students and Young Doctors*. Chișinău, 2020, p. 80-81. ISBN 978-9975-151-11-5.
16. **Colța A.** Valoarea prostatitei cronice abacteriene (NIH-III) asupra nivelului seric al PSA liber și total. În: *Buletinul Academiei de Științe a Moldovei. Științe Medicale*. Număr consacrat aniversării a 60-a de la fondarea IMSP Institutul Oncologic din Republica Moldova. Chișinău, 2020, 4(68), p.187.

- ✓ **National conferences**

17. **Colța A.,** Pleșacov A., Ghicavii V. Tratamentul endourologic al consecințelor prostatitei cronice abacteriene. În: Conferința Științifică anuală. Cercetarea în biomedicină și sănătate: Calitate, excelență și performanță. *Abstract Book*. 2021, p.268. ISBN 978-9975-82-223-7.

- **Invention patents and registration certificates**

18. Ghicavii V., **Colța A.** *Metodă de tratament al prostatitei cronice abacteriene sclerozante complicate cu obstrucție infravezicală.* Nr. 1527s 2020 0158. din 31.03.2021.
19. Ghicavii V., **Colța A.** *Metodă de tratament al prostatitei cronice abacteriene calculoase complicate cu obstrucție infravezicală.* Nr. brevet: 1526 s 2020 0157 din 31.03.2021.
20. Ghicavii V., **Colța A.** „*Particularitățile metodelor de tratament complex al prostatitei cronice abacteriene complicată cu scleroza prostatei.*”, Certificat de înregistrare cu Drept de autor. Seria O Nr 7287 din 20.06.2022.

- **Book chapter (Textbooks for university education)**

21. Urologie Andrologie Nefrologie Chirurgicală. Sub redacția prof. Dr. Emil Ceban. Ghicavii V., Pleșacov A., Vladanov I., **Colța A.** *Capitol 8. Hiperplazia benignă a prostatei și cancerul de prostată. p. 184-218.* Chișinău, 2020. 368 p. ISBN 978-9975-47-185-5.
22. Guide book. Farmacoterapia rațională în urologie și nefrologie.” Sub redacția: V. Ghicavii, E. Ceban și al. **Colța A.** – Tehnoredactarea și machetarea computerizată. Chișinău, 2022, 291 p., ISBN 978-9975-165-16-7.

ADNOTARE

Colța Artur „Tratamentul endourologic al obstrucției infravezicale provocată de consecințele prostatitei cronice abacteriene”, teză de doctor în științe medicale, Chișinău, 2023

Structura tezei: introducere, 5 capitole cu sinteza rezultatelor obținute, concluzii generale și recomandări practice, 222 de surse bibliografice, 5 anexe, 133 pagini de text de bază, 17 de tabele, 38 de figuri. Rezultatele obținute sunt publicate în 22 de lucrări științifice, inclusiv 17 de articole în reviste recenzate, 3 brevete de invenții. **Cuvinte-cheie:** scleroză, litiază, prostatolitiază, prostatectomie, prostatită abacteriană. **Scopul lucrării:** determinarea posibilităților de diagnostic al PCAB, al celor mai frecvente complicații și a eficienței tratamentului diferențiat endourologic transuretral al OIV, provocate de consecințele PCAB. **Obiectivele lucrării:** Studiul frecvenței și structurii OIV, provocată de PCAB și complicațiile ei cu determinarea posibilităților de aplicare și evaluare a eficacității intervențiilor endoscopice transuretrale (TURP, ITUP, laser) în PCAB obstructivă; analiza comparativă a frecvenței și gravității complicațiilor intra- și postoperatorii ale intervențiilor endoscopice cu elaborarea recomandărilor de prevenire și reducere a acestora; determinarea necesității și capacității entomoterapiei în prevenirea și minimizarea complicațiilor intra- și postoperatorii ale intervențiilor chirurgicale în PCAB obstructivă. **Noutatea și originalitatea științifică:** s-a analizat în premieră incidența și structura OIV, cauzată de PCAB și consecințele ei (scleroza prostatei și prostatita litiazică), rezultatele cercetărilor urodinamice și posibilele complicații intra- și postoperatorii cu determinarea diverselor modalități de tratament endourologic transuretral la pacienții cu PCAB obstructivă; s-au stabilit indicațiile și contraindicațiile intervențiilor endoscopice miniinvazive cu laser în tratamentul OIV, al consecințelor PCAB și contribuția lor în reducerea riscului de apariție a complicațiilor intraoperatorii cu aceeași eficiență ca cea a rezecției transuretrale (TUR); s-a demonstrat capacitatea entomoterapiei în PCAB de a reduce manifestările consecințelor sclerozate și litiazice. **Problema științifică importantă soluționată:** PCAB sclerozată și litiazică necesită o selecție diferențiată și adecvată a metodelor de tratament endoscopic transuretral, în funcție de starea clinico-morfologică (predominarea procesului sclerozat sau de formare a calculilor), de volumul, dimensiunile și localizare a acestora în prostată, a posibilităților de minimizare a complicațiilor intra- și postoperatorii la aplicarea acestora. Tratamentul entomologic anticipat al PCAB diminuează manifestarea proceselor sclerozate și de formare a calculilor prostatici, reduce semnificativ posibilele complicații ale intervențiilor endoscopice transuretrale. **Semnificația teoretică:** adoptarea metodologiei de investigare și evaluare a pacienților cu PCAB prin determinarea stării proceselor proteolitice ale organismului, markerilor biochimici ai inflamației factori importanți în dezvoltarea PCAB/SCDP, prin determinarea criteriilor diagnostice clinic veridice pentru diferențierea variantelor inflamatoare și neinflamatoare în PCAB. **Valoarea aplicativă a lucrării:** implementarea și utilizarea diferențiată a metodelor endoscopice transuretrale noi în tratamentul OIV, provocate de consecințele PCAB, a contribuit la extinderea diapazonului de folosire a lor, la ameliorarea rezultatelor tratamentului, reducerea duratei de spitalizare și de reabilitare a bolnavilor. S-au stabilit indicațiile și contraindicațiile pentru diverse metode (TUR, laser) și elaborat algoritmul de tratament al pacienților cu OIV, în funcție de caracterul țesutului sclerozat sau calculos, s-a evidențiat posibilitatea de a reduce frecvența eventualelor complicații la această categorie de pacienți. S-a implementat în practică metoda de tratament – rezecția laser (Ho:YAG), o alternativă în tratamentul sclerozei și prostatolitiazei, având o eficacitate înaltă și o rată mai mică a complicațiilor; o metodă eficientă de prevenire a complicațiilor în PCAB, bazată pe asocierea preparatelor entomologice cu unele intervenții endoscopice transuretrale miniinvazive (TUR, laser) cu obținerea micțiunii adecvate la majoritatea pacienților cu PCAB obstructivă. **Implementarea rezultatelor științifice:** rezultatele studiului au fost aplicate în procesul instructiv-didactic și curativ la catedra de urologie și nefrologie chirurgicală a USMF „Nicolae Testemițanu”, clinica de urologie și endourologie a SCR „Timofei Moșneaga” și secțiile de urologie ale IMSP municipale și raionale din Republica Moldova.

АННОТАЦИЯ

Колца Артур „Эндоурологическое лечение инфравезикальной обструкции, вызванной последствиями хронического абактериального простатита”, Диссертация на соискание ученой степени кандидата медицинских наук, Кишинев, 2023.

Структура диссертации: введение, 5 глав с обобщением полученных результатов, общие выводы и практические рекомендации, 222 библиографических источника, 5 приложения, 133 страниц основного текста, 17 таблиц, 38 рисунков. Полученные результаты опубликованы в 22 научных статьях. В том числе 17 статей в рецензируемых журналах, 2 патента. **Ключевые слова:** склероз, литиаз, простата, простатолитиаз, трансуретральная резекция, простатэктомия, абактериальный простатит. **Направление исследования и цели работы:** определить диагностические возможности ХАП, наиболее частые осложнения и эффективность дифференцированного трансуретрального эндоурологического лечения ИВО, вызванных последствиями ХАП/СХТБ. **Научная новизна:** Изучение частоты и структуры ИВО, определение возможностей применения и оценка эффективности эндоскопических вмешательств при ИВО, вызванном ХАП и его осложнениями; сравнительный анализ частоты и степени тяжести интра- и послеоперационных осложнений трансуретральных эндоскопических вмешательств, разработка рекомендаций по их профилактике и уменьшению в лечении ИВО, определение необходимости и возможностей энтомотерапии в профилактике и минимизации интра- и послеоперационных осложнений обструктивного ХАП. **Научная проблема, решаемая в диссертации:** ИВО, вызванная последствиями ХАП, такими как поствоспалительный склероз простаты и литиазный простатит, требует дифференцированного и адекватного выбора методов трансуретрального эндоскопического лечения, исходя из клинико-морфологического состояния, а также возможностей минимизации интра- и послеоперационных осложнений. Лечение энтомологическими препаратами уменьшает проявление склерозирующих процессов и образование камней простаты, значительно снижает возможные осложнения после операции. **Теоретическая значимость работы:** принятие методологии исследования и оценки пациентов с ХАП путем определения состояния протеолитических процессов организма, биохимических маркеров воспаления – важных факторов в развитии ХАП/СХТБ, путем определения клинически верных диагностических критериев для дифференциации воспалительных и не воспалительных заболеваний. **Практическая ценность работы:** внедрение новых трансуретральных эндоскопических методов лечения ИВО, вызванных последствиями ХАП. Дифференцированное использование этих методов в лечении способствовало расширению спектра их применения, улучшению результатов лечения, сокращению сроков госпитализации и реабилитации пациентов. Установлены показания и противопоказания к применению различных методов (ТУР, лазер) и разработан алгоритм лечения пациентов с ИВО. На практике реализован метод лечения – лазерная резекция (Ho: YAG), альтернатива в лечении склероза и простатолитиаза, обладающая высокой эффективностью и меньшей частотой осложнений; эффективный метод профилактики осложнений – сочетание энтомологических препаратов с некоторыми эндоскопическими вмешательствами позволяет добиться адекватного мочеиспускания у большинства пациентов. **Внедрение научных результатов:** результаты исследования были применены в учебном и лечебном процессах на кафедре урологии и оперативной нефрологии ГУМФ им. Николае Тестемицану, в клинике урологии и эндоурологии РКБ им. Тимофея Мошняги и отделениях урологии муниципальных и районных медицинских учреждений Республики Молдова.

ANNOTATION

Colța Artur „Endourologic treatment of infravesical obstruction caused by chronic nonbacterial prostatitis consequences” Ph.D. Thesis in Medical Sciences, 2023.

Structure of the thesis: introduction, 5 chapters with the synthesis of the obtained results, general conclusions and practical recommendations, 222 bibliographic sources, 5 annexes, 133 pages of basic text, 17 tables and 38 figures. The obtained results are published in 22 scientific papers. Including 17 articles in reviewed journals, 3 brevets of innovation. **Keywords:** fibrosis, lithiasis, prostate, lithiasis of prostate, transurethral resection, prostatectomy, nonbacterial prostatitis. **The Purpose of the paper:** to determine the diagnostic possibilities of chronic nonbacterial prostatitis (NBP), the most common complications and the effectiveness of the differentiated transurethral endourological treatment of after bladder obstruction, caused by the consequences of NBP. **Objectives of the thesis:** Study of the frequency and structure of after bladder obstruction, determination and possibilities of application and evaluation of the effectiveness of endoscopic treatment in after bladder obstruction caused by NBP and its complications; comparative analysis of the frequency and severity of complications in and after complications of transurethral endoscopic surgery, elaboration of recommendations, preventing in after bladder obstruction treatment, determination of the possibility and capacity of entomotherapy in preventing and minimizing intra and after surgery complications of obstructive NBP. **Scientific novelty and Originality:** the incidence and structure of after bladder obstruction, caused by NBP and its consequences, the results of urodynamic research and possible intra and after surgery complications with the determination of different types of endourology treatments in restoring the urinary flow after bladder at the patients with after bladder obstruction in fibrosis and lithiasis of the prostate; the indications and contraindications of LASER minimalinvasive endoscopic in the treatment of after bladder obstruction of NBP consequences have been established, in the same efficacy as transurethral resection (TUR); the possibilities of entomotherapy to significantly contribution for prevention and decrease of intra and after surgery transurethral complications with anti-inflammatory, antiproliferative and antifibrotic medication, used in NBP, has been demonstrated. **The scientific problem solved:** After bladder obstruction caused by the consequences of NBP such as post-inflammatory prostate fibrosis and prostate lithiasis, requires a differentiated and adequate application of transurethral endoscopic treatment methods, based on the clinical and morphologic condition, as well as the possibilities to decrease intra and after surgical complications. Treatment with entomological medications decrease the manifestation of fibrosis processes and the formation of prostatic calculi, significantly decrease the possible complications after surgery. **Theoretical significance of the study:** adoption of the methodology for investigation and evaluation of patients with NBP by determining the state of proteolytic processes of the body, biochemical markers of inflammation - important factors in NBP / CPPS development, by determining clinically correct criteria of diagnosis, to differentiate inflammatory and non-inflammatory variants in NBP. **The application value of the thesis:** the implementation of new transurethral endoscopic methods in the treatment of after bladder obstruction, caused by the consequences of NBP. The differentiated use of these methods in treatment has contributed to the extension of the range of their use, the improvement of treatment results, the decrease of the period of hospitalization and rehabilitation of patients. The indications and contraindications for various methods (TUR, laser) were established and the treatment algorithm of patients with after bladder obstruction was developed. The treatment method was implemented in practice - laser resection (Ho:YAG), an alternative in the treatment of fibrosis and lithiasis of prostate, having a high efficacy and a lower rate of complications; an effective method of preventing the complications - the combination of entomological drugs with some endoscopic interventions allows to obtain an adequate micturition at almost patients. **The implementation of scientific results:** the results of the study were applied into didactic process at the Department of urology and surgicalnephrology of Nicolae Testemițanu State University of Medicine and Pharmacy, in the teaching process of students, in postgraduate training of resident doctors - urologists and doctors in continuing medical education courses and in the clinical activity of the Urology and endourology department of PMI Republican Clinical Hospital „Timofei Moșneaga” and the urology departments of municipals PMI and district hospitals from the Republic of Moldova.

COLȚA Artur

**ENDOUROLOGICAL TREATMENT OF INFRAVESICAL
OBSTRUCTION CAUSED BY CHRONIC NONBACTERIAL
PROSTATITIS CONSEQUENCES**

321.22 – UROLOGY AND ANDROLOGY

Approved for publishing: _____-2023

Paper offset. Publishing offset.

Printing sheets: 1.50

Paper size 60x84 1/16

Print edition 30 copies

Order No. _____

Printing house SRL Print-Caro

Tel. (022) 85-33-86

MD 20___, Chișinău, 14 Astronom N. Donici str.